

# Missed anatomy: frequency and clinical impact

GIUSEPPE CANTATORE, ELIO BERUTTI & ARNALDO CASTELLUCCI

It is generally accepted that a major cause of the failure of root canal therapy is an inability to localize and treat all of the canals of the root canal system. The risk of missing anatomy during root canal treatment is high because of the complexity of the root canal system. All categories of teeth may have extra roots and/or canals, but the likelihood of finding aberrant canal configurations is higher in premolars and molars. In addition, lateral ramifications of the root canal system may be present in all teeth with a significant frequency, increasing the probability of leaving untreated spaces after root canal therapy. Prevention of missed anatomy starts with good pre-operative radiographs, even though radiographs have limitations in assessing the number of canals and the presence of accessory canals and anastomoses. A correct access cavity preparation is of central importance in localizing the orifices of the root canals. However, to find hidden canals, an adequate armamentarium is required; the dental operating microscope and/or high-power loupes, used in conjunction with a headlight system, will provide enhanced lighting and visibility, whereas ultrasonic tips and long shank round burs with small shaft diameters will allow a controlled and delicate removal of calcifications and other interferences to the canal orifices. The impact of missed anatomy on the outcome of endodontic treatment is difficult to assess, and the literature on this subject is limited; a promising approach for future investigation may be a comparison of the number of canals found in failed treatment cases and after re-treatment. The clinical impact of missed anatomy can be clearly demonstrated with a large number of re-treatment case reports available in the literature; in the majority of these cases, failure of endodontic therapy is associated with untreated canal space. Localization and treatment of this missed anatomy typically leads to complete clinical and radiographic healing.

## Introduction

The main objective of endodontic therapy is to prevent and, when required, to cure endodontic disease, apical periodontitis (AP) (1, 2). The achievement of this goal depends on several factors:

- elimination of surviving microorganisms in the root canal system through effective cleaning and shaping procedures (1–3);
- creation of a tight three-dimensional seal with an inert filling material (4); and
- blockage of any communication between the oral cavity and the periradicular tissue through a high-quality coronal restoration (3).

However, locating, cleaning, and shaping the entire canal system may present a difficult challenge in non-surgical endodontic treatment; aberrant canal configurations, accessory canals, bifurcations, isthmuses,

and anastomoses are often difficult to identify, thus causing incomplete cleaning and filling (Fig. 1). The impact of these untreated canal spaces on the outcome of endodontic treatment is difficult to assess and the endodontic literature on this specific topic is scarce; however, it is generally accepted that an inability to recognize the presence of and to adequately treat all of the canals of the endodontic system may be a major cause of the failure of root canal therapy (4–11). The frequency and risk of missed anatomy are strictly linked with the complexity of the root canal system; good knowledge of the potential aberrant canal morphology in maxillary and mandibular teeth will help clinicians to successfully recognize and treat these difficult cases. Consequently, this report on missed anatomy will begin with a review of the possible canal configurations in maxillary and mandibular teeth.

## Risk of missing canals in maxillary and mandibular teeth

### Maxillary central and lateral incisors

The endodontic anatomy of maxillary central and lateral incisors is generally simple with one canal in one root. Vertucci (4, 9) reported a type I configuration (one canal) for maxillary incisors in 100% of teeth. Morphological variations in maxillary anterior teeth may occur with a frequency of up to 2% in central incisors and 10% in lateral incisors (12); in a Turkish population, this frequency can increase to 22% in lateral incisors (13). When more than one canal is present, the possible configurations include: Vertucci's type II with two canals joining in one apical foramen (12–14); Vertucci's type IV with two separate canals in one root (15–19); two canals in two separated roots (Fig. 2a–c)



Fig. 1. A transparent mesial root of a mandibular molar demonstrating an intricate root canal system. After preparation with rotary nickel-titanium files and a 1-minute final ultrasonic irrigation with sodium hypochlorite, the canal system was injected with ink.

(20–29); and two or more canals associated with abnormal development of the tooth such as gemination, fusion, concrescence, and dens invaginatus (Fig. 3a–c). Furthermore, Walvekar & Behbehani (30) published a case report of a maxillary lateral incisor with three canals and Mangani & Ruddle reported a central incisor with four canals (31). Summarizing, one canal in one root should be expected in maxillary incisors; morphological variations are possible but easy to recognize during the clinical and radiographic examination. Incisors with normal crown and root but with two canals are rare and difficult to identify because the two canals (labial and lingual) may be superimposed (15–19). An adequate pulp chamber opening and observation of intra-operative radiographs may help in these difficult cases.

### Maxillary canines

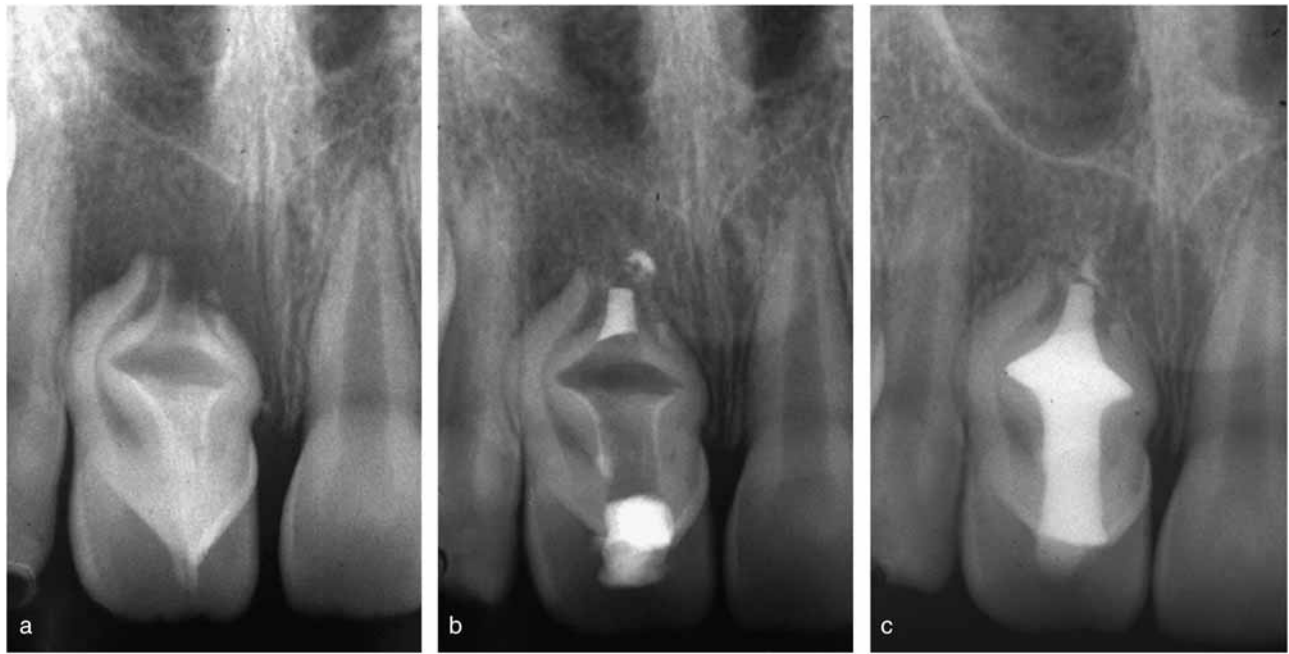
Maxillary canines have one canal in one root in almost 100% of cases (8, 9). Morphological variations are rare but have been reported, mainly in a Turkish population, where maxillary canines can present more than one canal in 9% of cases in men and 4% of cases in women (12).

### Maxillary premolars

The most common canal configuration for the *maxillary first premolar* is Vertucci's type IV (two separate canals in one root) with a frequency of about 60–65% (9, 12). Another canal morphology, Vertucci's type V, with one canal that extends from the pulp chamber to

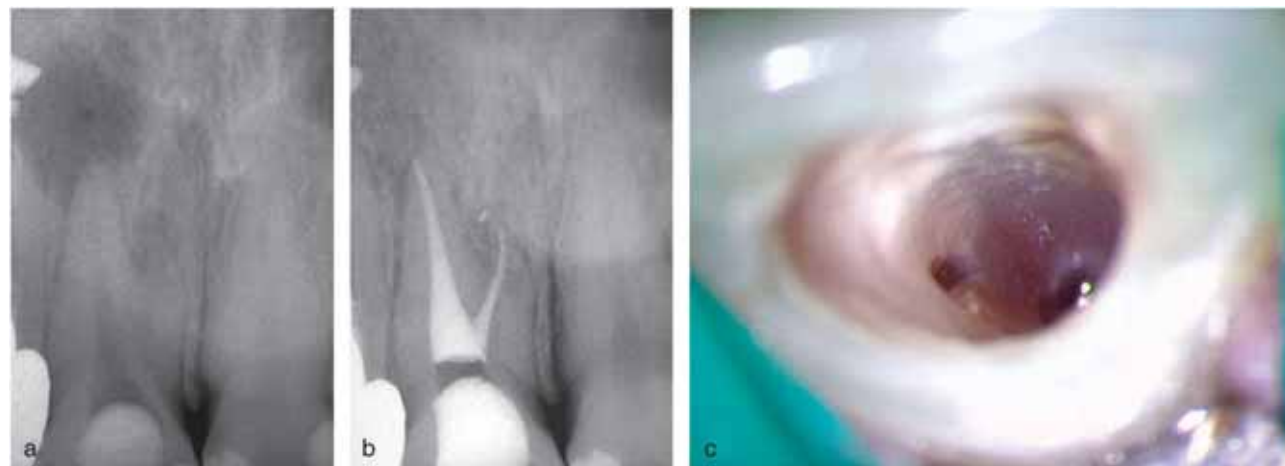

Fig. 2. Endodontic treatment of maxillary central incisors with two roots. (a, b) Pre-operative and post-operative radiographs. (c) Position of the two canal orifices.



**Fig. 3.** Non-surgical treatment of a central maxillary incisor with dens invaginatus and a vital pulp. The tooth had the root canal compressed within the wall around the invagination, whereas the invagination extended into the roots and exited apically through a large second foramen. (a) The pulp tissue within the root canal was vital. (b) Intra-operative radiograph after the obturation of the apical part of the invagination and the direct pulp capping of the root canal, both carried out with MTA. (c) The remaining invaginated space was filled with injected warm gutta-percha, and the access opening was finally restored with composite resins.

mid-root, where it divides into two canals, can be found in 6–7% of cases (9, 12). In about 8–9% of cases, the maxillary first premolar can have one canal and in 16–18%, two canals joining into one (9, 12). Furthermore, maxillary first premolars can have three canals (mesio-buccal [MB], disto-buccal [DB], and palatal) in 2.5–5% of cases with a canal and root disposition so similar to that of adjacent first molars that they are sometimes called small molars or ‘radiculous’ (32–34) (Fig. 4a–c).

*Maxillary second premolars* have one canal in one root in 38–48% of the cases, two canals joining in one root in 20–22% of the cases, one canal separated into two canals that rejoin in the apical third (Vertucci’s type III) in 5–10% of the cases, two canals in two roots in 10–20% of the cases, and one canal that splits and exits as two canals (Vertucci’s type V) in 6–9% of the cases (9, 12). More rare, but possible configurations are two canals that join and separate again in the apical third (Vertucci’s type VI) with a frequency of 2–5%, one canal separated into two canals that rejoin and split again (Vertucci’s type VII) with a frequency of 1–2%, and three separate canals with a frequency of 1–2% (9, 12). Three-rooted maxillary second premolars have

been reported by Barkhordar & Sapone (35), Ferreira et al. (36), and Low (37), while a case of three-rooted maxillary first and second premolars has been reported by Soares & Leonardo (33). Clinicians should be very cautious when treating maxillary premolars because of the extreme variability of their anatomy; the risk of missing a canal in these teeth is always present (Fig. 5a–d). To avoid errors, a careful examination of the pulp chamber floor should be performed, looking for the position and symmetry of canal orifices (38). Furthermore, a minimum of two diagnostic radiographs should be taken with parallel and shift cone angle techniques. In fact, using angled radiographs, Sardar et al. could identify a significantly higher number of premolars with two canals (39). Sieraski et al. (40) found that whenever the mesio-distal width of the mid-root image was equal to or greater than the mesio-distal width of the crown, the premolar most likely had three roots.

### Maxillary first molars

There is a wide range of variation in the literature on maxillary first molars with respect to the number of

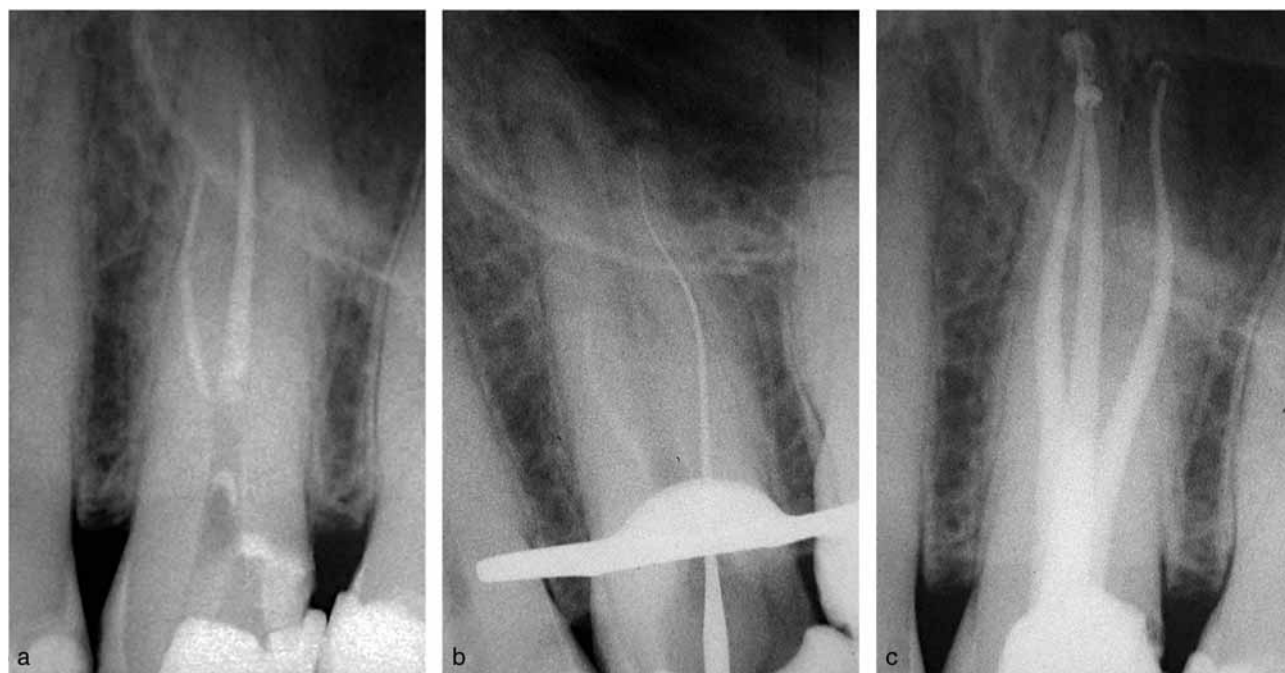


Fig. 4. (a) Re-treatment of three-rooted maxillary first premolars with only two canals ‘partially’ treated. (b) Negotiation and working length of the third missed canal. (c) Post-operative radiograph.

canals in each root, the number of roots, and the incidence of root fusion (41). The following factors contribute to the variation found in these studies:

- high variability and complexity of maxillary molar morphology (42);
- ethnic background (9, 43), age (44, 45), and gender (12, 46) of the population studied;
- design (clinical versus laboratory) and methods of the study (41, 47); and
- authors’ definition of what constitutes a canal (41). A separate canal is defined in some studies as a separate orifice found on the floor of the pulp chamber (48), a canal that can be instrumented to a depth of 3–4 mm (49) or to a depth of 16 mm from the cusp of an intact tooth (50), or a treatable canal with a separate apical foramen (51).

In 2006, Cleghorn et al. (41) reviewed the literature with respect to the root and canal systems in maxillary first molars. The results of this study indicated that maxillary first molars had three roots in 96.2% of the 416 teeth examined. Two roots were found in 16 (3.8%) of the teeth studied. The incidence of one root or four roots was very rare. Fusion of two or more roots occurred approximately 5.2% of the time (41). Cleghorn et al. reviewed the canal configuration in mesio-buccal roots of maxillary first molars in 34 studies (comprising 8399 teeth). Two or more canals were found in 56.8% of the

teeth in a weighted average of all 34 studies (41) (Fig. 6a–d). One canal was found in 43.1% of these roots. A single apical foramen was found 61.6% of the time, while two separate apical foramina were present 38.3% of the time (41) (Fig. 7a and b). The canal morphology of the disto-buccal and palatal roots was reported in 14 studies that included 2576 teeth (41). The most common canal system configuration of the disto-buccal root was a single canal (98.3%). Two canals were found 1.7% of the time. A single apical foramen was present 98% of the time. The palatal root had a single canal and a single foramen 99% and 98.8% of the time, respectively (41). C-shaped canals are very rare in maxillary first molars, with an incidence of about 0.1% (41, 52). C-shaped root canal morphotypes result from a fusion of the disto-buccal and palatal roots and may extend to the apical third of the fused roots (52).

Many unusual canal configurations and anomalies in maxillary first molars have been documented in case reports. Maxillary first molars with two palatal roots were described by Stone & Stroner (53), Hülsmann (54), Baratto-Filho et al. (55), and Barbizan et al. (56), whereas a case with five roots (two MB, one DB, and two palatal roots) and five canals was reported by Barbizan et al. (56). Single palatal roots with two separate canals were reported by Thews et al. (57), Stone & Stroner (58), and Hartwell & Bellizzi (59), whereas palatal roots with a tri-furcated canal were

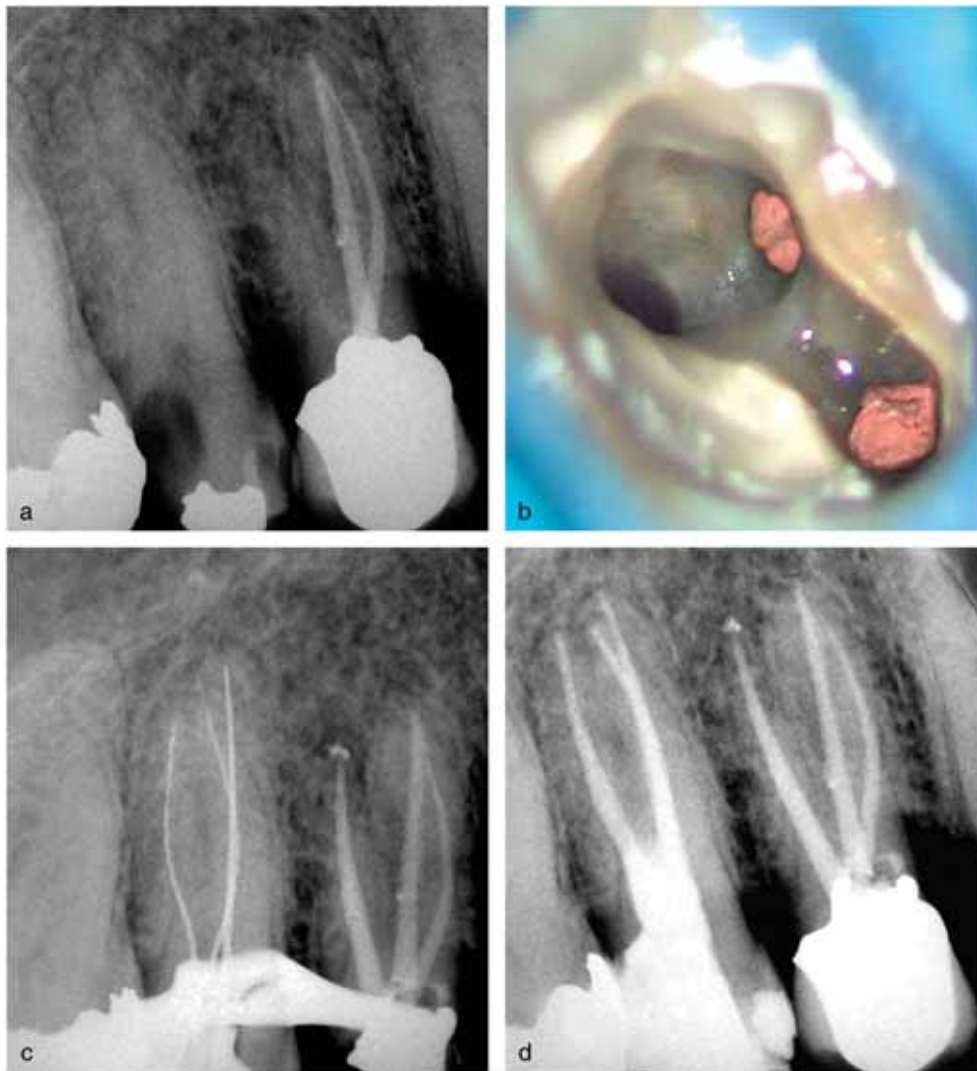

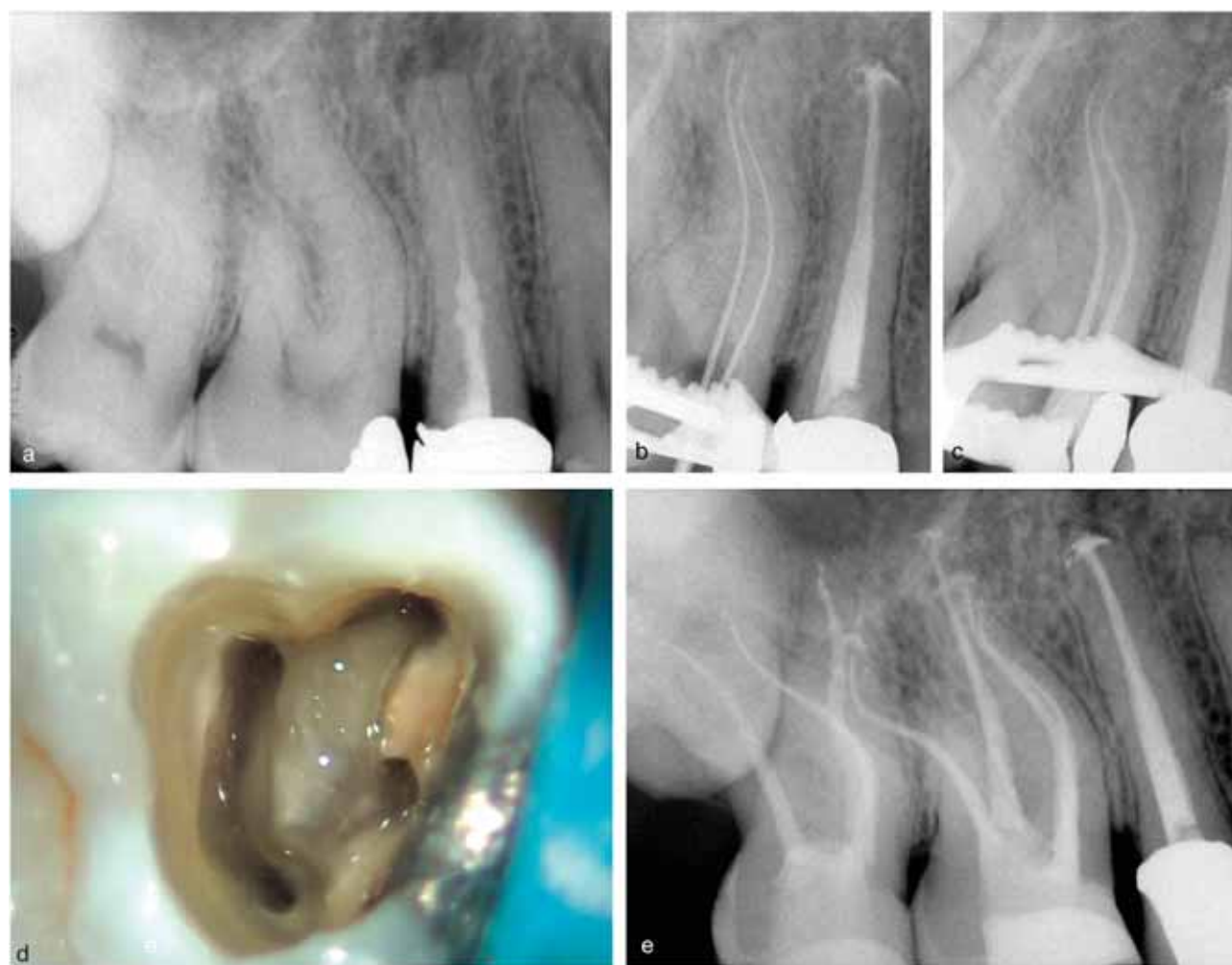Fig. 5. Endodontic treatment of the first and second right maxillary premolars, both three-rooted. The first premolar showed an old adequate treatment in two roots but a third missed root with a periapical radiolucency. The second premolar showed extensive caries extending to the pulp chamber. (a) The patient suffered from both pulpitis and apical periodontitis symptoms. (b) The missed canal in the first premolar after cleaning and shaping. (c) Working length radiograph for the second premolar with post-op of the first premolar. (d) One-year follow-up radiograph showing good healing of the first premolar and no sign of infection in the second premolar.

described by Wong (60) and Maggiore et al. (61). Cases with three separate canals in the mesio-buccal root were reported by Martinez-Berna & Ruiz-Badanelli (62) and Beatty (63), whereas two canals in the disto-buccal root were found by Martinez-Berna & Ruiz-Badanelli (62) and Bond (64). The maxillary first molar is probably the tooth that presents the higher risk of missing canals during an endodontic treatment. The considerable discrepancy between clinical and laboratory results in the incidence of the second mesio-buccal (MB2) canals demonstrates that the MB2 is often not found during endodontic treatment (10). The significant differences between the percentage of

MB2 canals located in the initial treatment and those found during re-treatment demonstrate that this canal, when not found, is associated with endodontic failure (10, 65). The possibility of two canals in the disto-buccal and palatal roots further increases the possibility of errors during the treatment of these teeth (Fig. 8a and b).

### Maxillary second molars

Most studies concerning the canal morphology of maxillary second molars reported that the majority of these teeth have three roots (65, 66). In a review and radiographic survey of 1200 maxillary second molars,



**Fig. 6.** Endodontic re-treatment of the second right maxillary premolar and treatment of the first and second molars. (a) Pre-operative radiograph. (b, c) Post-op of the premolar and working length of the two separate mesio-buccal canals of the first molar. (d) The pulp chamber of the first molar with four separate canals. (e) One-year follow-up radiograph: the second molar had three canals.

Libfeld & Rotstein reported that 90.6% of these teeth had three roots with three or four canals, whereas 6% of the teeth were two-rooted, 3% had a single root, and 0.4% had four roots (66). Zmener & Peirano (67), Fahid & Taintor (68), and Jafarzadeh et al. (69) described cases with three buccal roots fully separated, and Alani (65) reported a case of bilateral four-rooted maxillary second molars that had two buccal and two palatal roots.

Vertucci investigated the canal configuration of 100 maxillary second molars and found, in the mesio-buccal root, one canal in 71% of cases, two canals joining in 17% of cases, and two separate canals in 12% of cases. Disto-buccal and palatal roots presented a single canal in 100% of cases (8, 9). C-shaped canals are very rare in maxillary second molars (70).

### Recommended clinical approach in maxillary molars

1. Take two diagnostic radiographs with parallel and mesial or distal horizontal angles and assess the anatomy and number of roots.
2. Carefully remove the pulp chamber roof and abundantly flush the chamber with full-strength warm sodium hypochlorite.
3. Following the dark developmental line on the pulp chamber floor with a DG16 endodontic probe, locate the orifices of the three main canals (MB1, DB, and palatal).
4. Negotiate the main canals and take a working length radiograph on a distal projection with #10 or

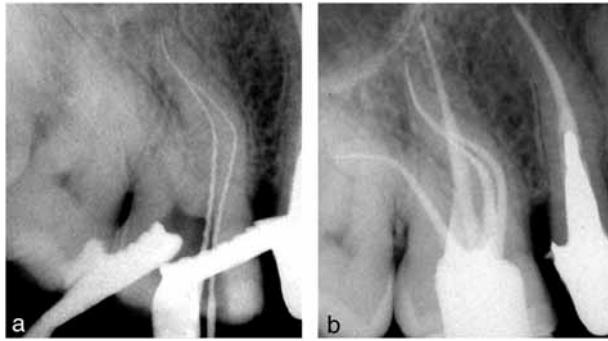


Fig. 7. Endodontic treatment of a maxillary first molar with two canals joining in the mesio-buccal root. (a) Working length of the mesio-buccal root showing two canals joining at the apical third. (b) Post-operative radiograph.

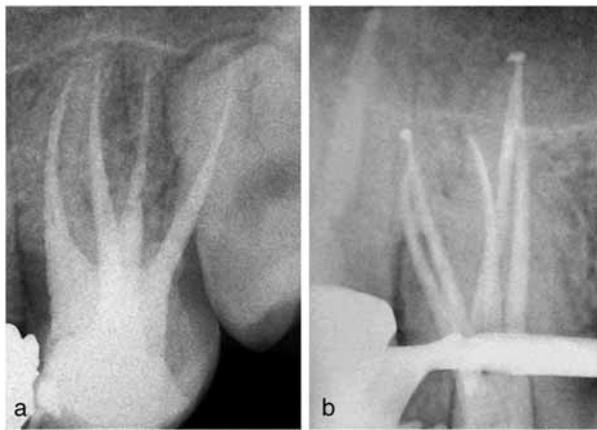


Fig. 8. Variation of the root canal morphology of maxillary molars. (a) A second molar with two palatal roots. (b) A first molar with two disto-buccal and two joining palatal canals.

#15 k-files inserted. If the instrument appears to be off center in the root, a second canal should be suspected (10, 11).

5. Visualize the white dentinal layer in the pulp chamber between the MB1 and the palatal canals and carefully remove it with ultrasonic tips with rounded or with long shank round burs with small shaft diameters such as Munce Discovery Burs (CJM Engineering Inc.) or Mueller burs (Brasseler Inc., Savannah, GA, USA) to create a groove on the pulp chamber floor. This dentinal layer may partially or totally hide the MB2 orifice (Fig. 9a–c).
6. Localize the orifice of the MB2 canal with the DG16 probe and try to negotiate it with an adequate file such as the Maillefer C+ File (Dentsply Maillefer, Ballaigues, Switzerland).
7. Preflare the MB2 up to a #15 hand file and measure the working length with an electronic apex locator.

Insert two files into the MB1 and MB2 canals and assess whether they are joining or separate. Complete preparation in all canals.

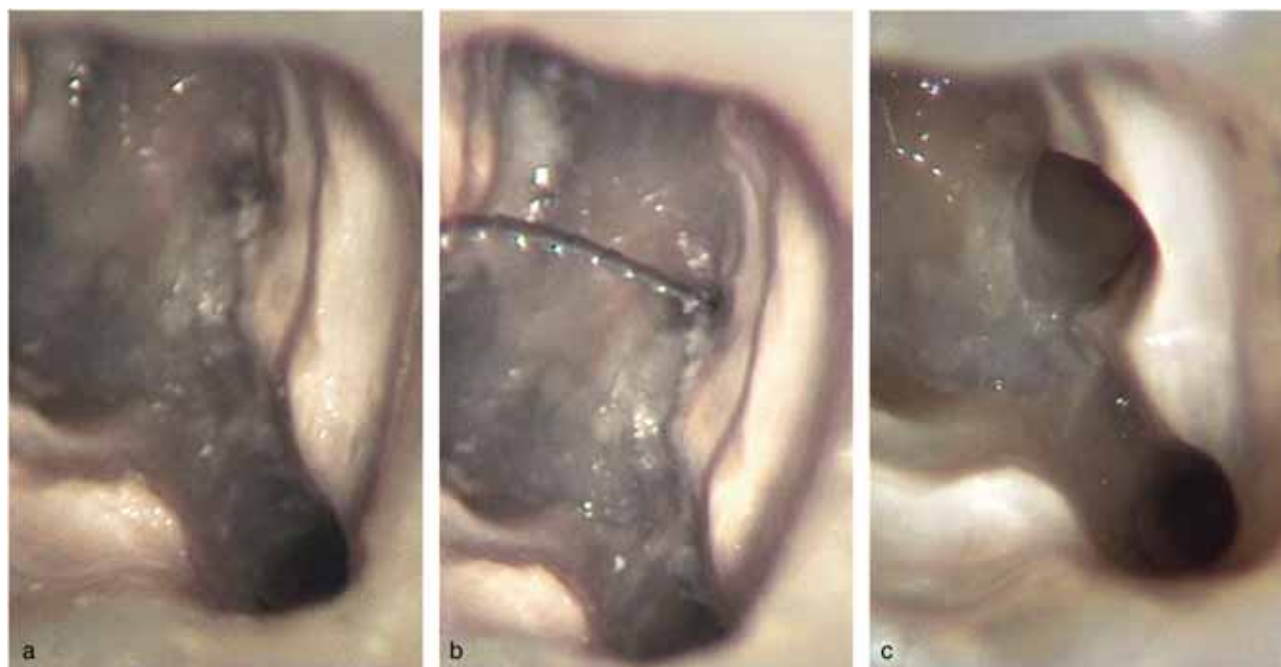
8. Carefully observe the pulp chamber floor, looking for additional canal orifices. The effervescence of sodium hypochlorite on the pulp at the orifices of these extra canals may help to localize them.
9. Use the operating microscope and/or high-power loupes with appropriate illumination in all phases.

### Mandibular central and lateral incisors

The morphology of mandibular central and lateral incisors is very similar. Many studies have examined the root canal systems of these single-rooted teeth, confirming that it is not as simple as it may appear to be on standard periapical radiographs. Vertucci studied the root canal morphology of 300 extracted mandibular anterior teeth and found two canals in 30% of mandibular central incisors and in 25% of mandibular lateral incisors (9). In a study on 1085 extracted mandibular incisors, Miyashita et al. (71) found one single canal in 85% of teeth, two joining canals in 12% of cases, and two independent canals in 3% of the teeth. In an investigation on 100 mandibular anterior teeth, Kartal & Yanikoglu (72) identified two new root canal types, which had not been previously identified. The first configuration was a 2-3-1 type (two separate canals extend from the pulp chamber to mid-root where the lingual canal divides into two; all three canals then join in the apical third). The second new configuration was a 1-2-1-3 type (one canal divides into two in the middle third of the root, rejoins to form one canal, which again splits and exits as three separate canals) (9, 72). Although some of the morphological variations may depend on different ethnic backgrounds, two canals should be expected in about one-quarter of mandibular incisors. This proportion is not found clinically by practitioners during root canal treatment because of the failure of the dentist to recognize the presence of the second canal (71, 73). Access cavities with appropriate inciso-gingival extension prepared under magnification may be very helpful when treating these difficult, high-risk teeth (Fig. 10a and b).

### Mandibular canines

Pecora et al. (74) studied the internal anatomy, direction, and number of roots of 830 extracted mandibular canines. Using a clearing method, the



**Fig. 9.** Localization and negotiation of the MB2 canal in maxillary molars. (a) After localization of the MB2 orifice with a DG 16 endodontic probe. (b) Initial negotiation of the MB2. (c) After removal of dentin interferences with ultrasonic tips and cleaning and shaping.

authors found that 98.3% of these teeth had a single root, 92.2% presented with one canal and one foramen, 4.9% had two canals and one foramen, and 1.2% had two canals and two foramina. The incidence of two-rooted canines was low, 1.7%, always with two canals. The total frequency of mandibular canines with two separate canals was 2.9% in this study. The results of Pecora's study were similar to those reported by Vertucci in another study on 100 mandibular canines (8). Furthermore, Heling et al. (75) reported a case with a mandibular canine with two roots and three canals. Mandibular canines with two roots are not difficult to identify by a careful examination of the diagnostic radiographs taken with parallel and mesial or distal horizontal angle techniques. However, it is more difficult to recognize two canals in single-rooted canines. Magnification and correct pulp chamber openings will help to avoid errors on these teeth.

### **Mandibular first premolars**

A comprehensive literature review of the root and root canal morphology of the mandibular first premolar was published by Cleghorn et al. in 2007 (76). Approximately 98% of the 6700 teeth analyzed in this review were single-rooted. The incidence of two roots was

1.8%. Three roots and four roots were found in 0.2% and 0.1% of the teeth, respectively (76). Studies of the internal canal morphology revealed that a single canal was present in 75.8% of the teeth. Two or more canals were found in 24.2% of the teeth studied. A single apical foramen was found in 78.9% of the teeth, whereas 21.1% had two or more apical foramina (76). Canal configurations in mandibular first premolars may vary significantly with respect to ethnicity, race, and sex. In a study of mandibular first premolars in a Chinese population using the cross-section method, Lu et al. (77) found a single canal (type I) in 54% of the teeth, two canals in 22% of the teeth, C-shaped canals in 18% of the teeth, and circumferential canals (a single canal splitting into three or four canals at the apical third) in 6% of the cases. Uncommon but possible morphological anomalies of the mandibular first premolar are two canals in two roots (78), three canals in three separate roots (79–81), three canals in one root (82), and a single main canal that splits into three separate canals and apical foramina (83) (Fig. 11a–h).

### **Mandibular second premolars**

The morphology of this tooth is generally more regular and simple than that of the first premolar. Vertucci (8)



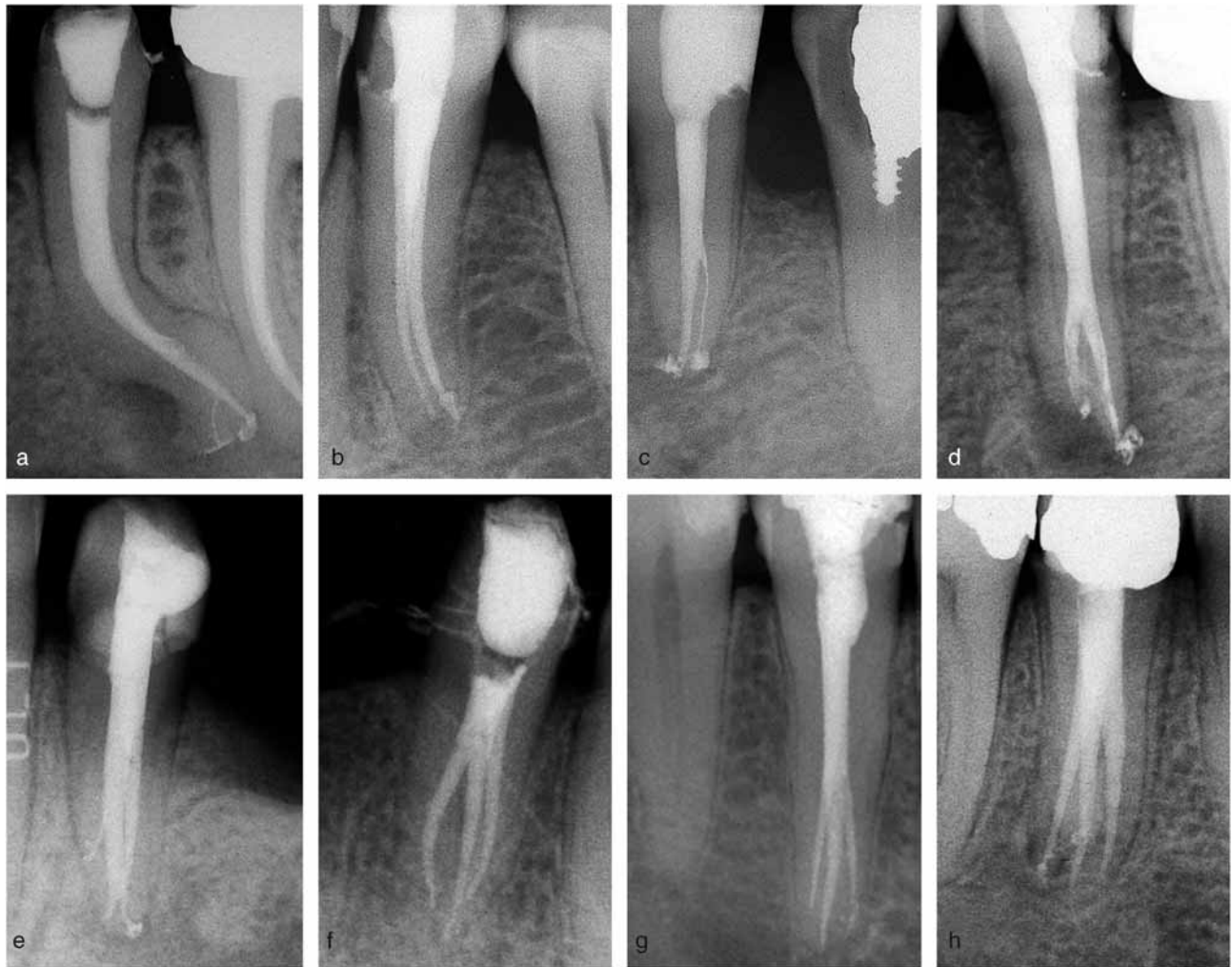

Fig. 10. Variability of the root canal morphology of mandibular premolars. (a) One single canal with apical ramifications. (b, c) Two separate canals in one root. (d) Two canals in two roots. (e) Two canals with ramifications that join at the root middle third and split again apically. (f-h) Three canals.

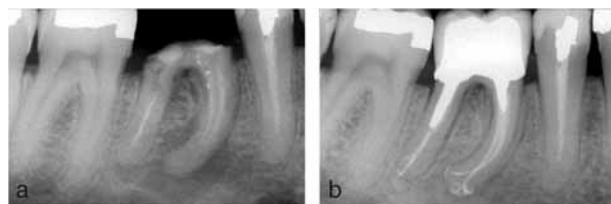


Fig. 11. (a) Re-treatment of a mandibular first molar with a large periapical radiolucency. (b) Two-year follow-up radiograph showing two separate canals in the mesial root, each with apical ramifications and a single canal in the distal root with an accessory canal. Good healing of the periapical lesion.

found that the second premolar had one root canal at the apex in 97.5% of the teeth studied and two canals in only 2.5%. Mandibular second premolars may have three canals, but the frequency of this configuration is scarce, appearing to range from 0% to 0.4% (84).

Mandibular second premolars may present various root canal aberrations: premolars with three canals were described by El Deeb (85), Rödiger & Hülsman (86), and DeMoor & Carlberson (87); cases with four canals were reported by Bram & Fleisher (88), Holtzman (89), and Rhodes (90); and a case of a mandibular second premolar with five canals was published by Macri & Zmener (91).

Mandibular premolars, because of their complex canal systems, are often considered the most difficult of all teeth on which to perform successful endodontic treatment (12, 73, 76). When endodontically treating these teeth, a minimum of two pre-operative radiographs with different cone angulations should be taken and carefully interpreted (73). In addition, the operating microscope should be used to facilitate the observation of anatomical landmarks in the pulp

chamber floor that may help to identify supplementary root canals or root canal aberrations (87). Furthermore, the operating microscope can often enable the clinicians to directly visualize the point where the main canal bi- or tri-furcates and the orientation of canal orifices. However, if the level of the furcation is deep and canal orifices are calcified, their identification may be difficult, even with a microscope.

### Mandibular first molars

In a Caucasian population, the majority of *mandibular first molars* are two-rooted, with various canal configurations in both mesial and distal roots. According to Vertucci's classification, *the mesial root* presents with two separate canals at the apex in 59% of teeth, two canals joining with a single apical foramen in 28% of teeth, a single canal in 12% of teeth, and three canals in 1% of teeth (8, 9) (Fig. 12a and b). In other studies, the frequency of a middle mesial canal in the mesial root of mandibular molars varies between 1% and 7% of teeth (92–99). The three mesial canals can be separate (92–95) or can join into two and exit with two apical foramina (96–99). Furthermore, some authors reported cases of mesial roots with four canals, although this finding should be considered rare (100, 101). When an additional mesial canal is present, it is located between the two main canals and its orifice is often hidden by a dentinal projection of the pulp chamber wall. This layer of dentin can be differentiated from the pulp chamber floor because its color is lighter and similar to the dentin layer that hides the MB2 orifice in maxillary molars. An operating microscope and ultrasonic tips or long shank round burs should be used to

visualize and carefully remove the dentinal strip, respecting the pulp chamber floor, thus finding the extra canal orifices. *Distal roots* of mandibular first molars, in ethnic Europeans, have one single canal in about 70% of teeth, two canals joining into one in 15%, two separate canals in 5%, one canal that splits into two in 8%, and one canal splitting into two canals that rejoin into one at the apical third in 2% of the cases (8) (Fig. 13a and b). Also for the distal root, aberrant cases with three canals have been reported in the endodontic literature (102–104). On the whole, distal roots present with two or more canals in about 30% of the cases. The access opening of the pulp chamber in a lower molar should be adjusted to locate the orifice of the second distal canal. The symmetry, shape, and position of canal orifices and the developmental root fusion lines should be carefully evaluated; if only a narrow, round distal canal orifice is found that is not centered in the root, another canal orifice should be suspected (38).

A major variant of the two-rooted morphology in the mandibular first molar is the presence of a supernumerary root located disto-lingually [*radix entomolaris* (RE)] or mesio-buccally [*radix paramolaris* (RP)] (Fig. 14) (105, 106). The rate of occurrence of this root dysmorphia in Caucasians (107) and Africans (108) is less than 5%, whereas in populations with Mongoloid traits (such as the Chinese, Inuit, and Native Americans), RE occurs with a frequency that ranges from 5% to more than 30% (109, 110). A buccally located RP is very rare and occurs with a prevalence of less than 0.5% (105, 106). The dimensions of RE can vary from a short conical extension to a 'mature' root with a normal length and root canal

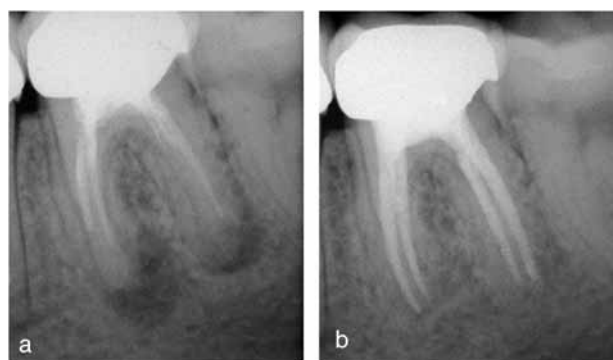

Fig. 12. Re-treatment of a mandibular molar with four separate canals. (a) Pre-operative radiograph. (b) Three-year follow-up.

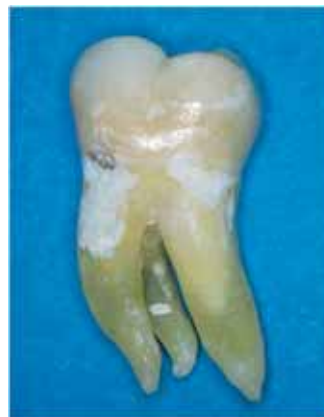

Fig. 13. An extracted mandibular molar with an entomolaris root.

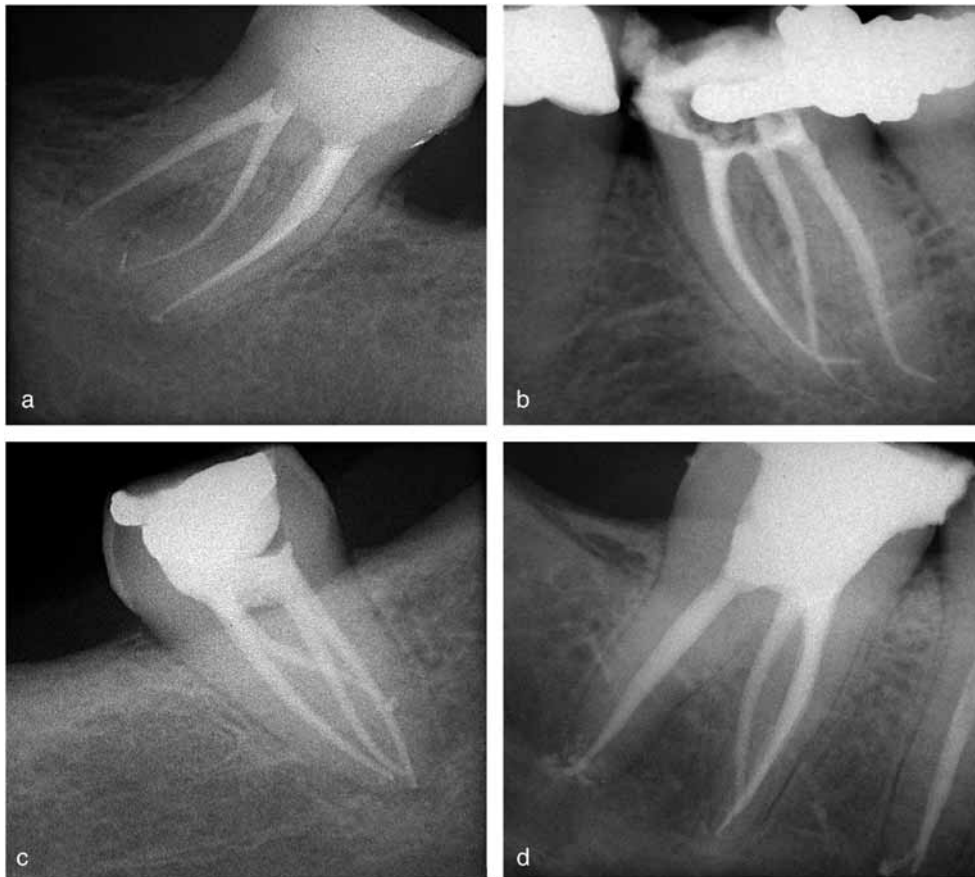


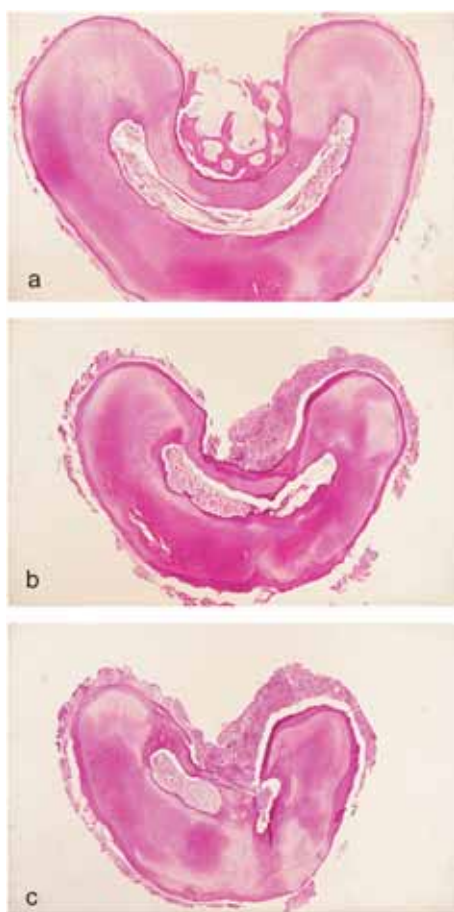
Fig. 14. (a–d) Four cases of mandibular molars with a third entomolaris root.

(105). In general, RE is smaller than the disto-buccal and mesial roots and can be separate from or partially fused with the other roots (105, 106, 111, 112). The clinical approach, when the presence of a supernumerary root is suspected, should be based on accurate radiographic diagnosis, clinical inspection, and pulp chamber opening. An unclear view or outline of the distal root contour or the root canal, in the pre-operative radiograph, can indicate the presence of a 'hidden' root (105, 112). A second radiograph, taken from a more mesial or distal angle ( $30^\circ$ ), generally reveals the profile of the RE (105). Clinical inspection of the tooth crown and of the cervical morphology of the roots by means of periodontal probing can facilitate identification of an additional root. An extra cusp (tuberculum paramolare) or a more prominent disto-occlusal or disto-lingual lobe, in combination with a cervical prominence or convexity, can indicate the presence of an additional root (105). The orifice of the RE is located mesio-lingually from the main distal canal, thus requiring a more rectangular or trapezoidal outline form of the access cavity. A dark developmental

line on the pulp chamber floor, carefully explored with an endodontic probe, can indicate the precise location of the RE canal orifice. An operating microscope can be very useful, especially in cases where the orifices are covered by a calcification that can be easily removed with ultrasonic tips or long shank round burs (105) (Fig. 15a–d).

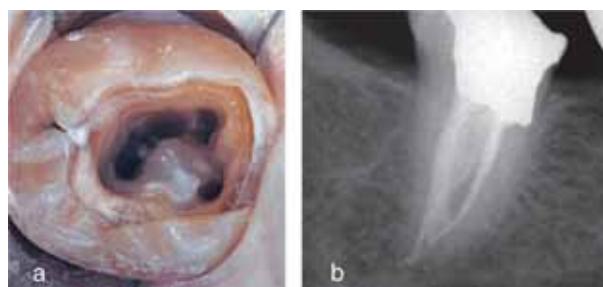
### Mandibular second molars

In a study on 149 mandibular second molars, Manning found that 76% of the teeth had two roots, 22% had one root, and 2% had three roots (113). In a study on 100 mandibular second molars, for the mesial root, Vertucci reported a single canal in 27% of the teeth, two canals joining in 38%, and two separate canals in 35% of the teeth (8). In the distal root, Vertucci found a single canal in 92% of the teeth, two canals joining in 3%, and two separate canals in 5% of the teeth (8). The presence of three canals in the distal root of a second mandibular molar has been reported by Beatty & Krell (114). Single-rooted mandibular second molars may



**Fig. 15.** Histological sections of a C-shaped mandibular second molar. (a) At the root coronal. (b) Middle third. (c) Apical third.

have the same canal configuration as two-rooted teeth or they can show a C-shaped canal system, characterized by the presence of a fin or a web connecting the individual root canals (113, 115–117). The formation of a C-shaped root and root canal system may depend on the failure of the Hertwig's epithelial root sheath to fuse on the lingual or buccal root surface (117). The prevalence of C-shaped canals reported in a Caucasian population is between 2.7% and 7.6% (56–58); however, in other ethnic groups, the prevalence can be significantly higher, with up to a 31.5% incidence rate reported in a Chinese population (115). The C-shaped canal system can assume many variations in its configuration. Fan et al. (118), using micro-computed tomography ( $\mu$ CT), investigated the C-shaped canal configurations of 58 mandibular second molars from the pulp chamber to the apex at 0.5 mm intervals. The canal shape at each level was classified into the following five categories:

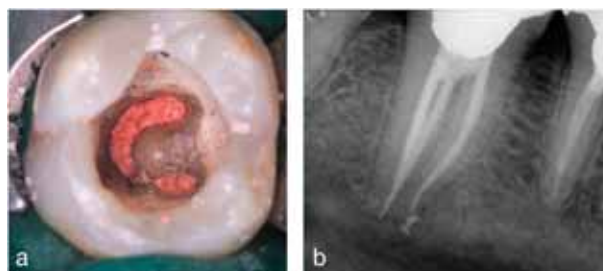


**Fig. 16.** Anatomy of C-shaped molars (Case 1). (a) Access cavity showing a main C-shaped canal with an additional MB canal. (b) Post-operative radiograph showing a complex canal system.

- Category C1: an uninterrupted 'C' outline with no separation or division;
- Category C2: a semicolon canal shape resulting from a discontinuation of the 'C' outline;
- Category C3: two or three separate canals with an isthmus linking them;
- Category C4: only one round or oval canal; and
- Category C5: no canal lumen could be observed.

The majority of C-shaped canal systems demonstrate an uninterrupted 'C' configuration at the canal orifice; however, the cross-sectional shape may vary drastically along the root in teeth with C1, C2, or C3 configurations. Categories C4 and C5 are mostly seen in cross-sections near the apex (118) (Fig. 16a–c).

Mandibular molars with C-shaped canals present a challenge with respect to their cleaning, shaping, and obturation. This is especially true when it is uncertain whether a C-shaped orifice found on the floor of the pulp chamber may continue to the apical third of the root. An operating microscope can be an invaluable aid in locating the areas where the main C-shaped canal splits into two or three canals and identifying the isthmuses between them (Fig. 17a and b). Irrigation of



**Fig. 17.** Anatomy of C-shaped molars (Case 2). (a) Access cavity after the obturation showing a continuous C-shaped canal. (b) Post-operative radiograph showing a division of the C-shaped canal into three canals: two distal joining at the root middle third and one mesial.

C-shaped canals should be carefully optimized using ultrasonic files to dynamically activate the irrigating solutions. In fact, the use of 1-min ultrasonic irrigation before obturation may increase canal and isthmus cleanliness (119, 120). Obturation techniques based on warm gutta-percha vertical condensation should be preferred in C-shaped canals because they develop high condensation forces, thus allowing three-dimensional fillings especially of the more intricate areas of these difficult canals (121) (Fig. 18a and b).

### Risk of missing accessory canals in maxillary and mandibular teeth

Root canal anatomy can be complicated by lateral ramifications projecting with different angles and

directions from the main canals. Lateral ramifications can exit on the external surface of the root with single or multiple foramina or they can connect two or more canals in the same root (anastomosis, isthmuses). Lateral ramifications may be present in all tooth categories with a significant frequency: De Deus, in an *in vitro* study on 1124 cleared teeth, found lateral ramifications in 27.4% of the examined teeth (122), whereas Rubach & Mitchell, in another study on extracted teeth, reported a 45% prevalence (123). Martic et al. (124) and Karagoz-Kucukay (125) investigated the frequency of accessory canals in anterior teeth, reporting an incidence of 33.3% and 32%, respectively, whereas Venturi et al. (126) found accessory canals in 100% of the examined maxillary molars. Cantatore et al. (127) evaluated the frequency

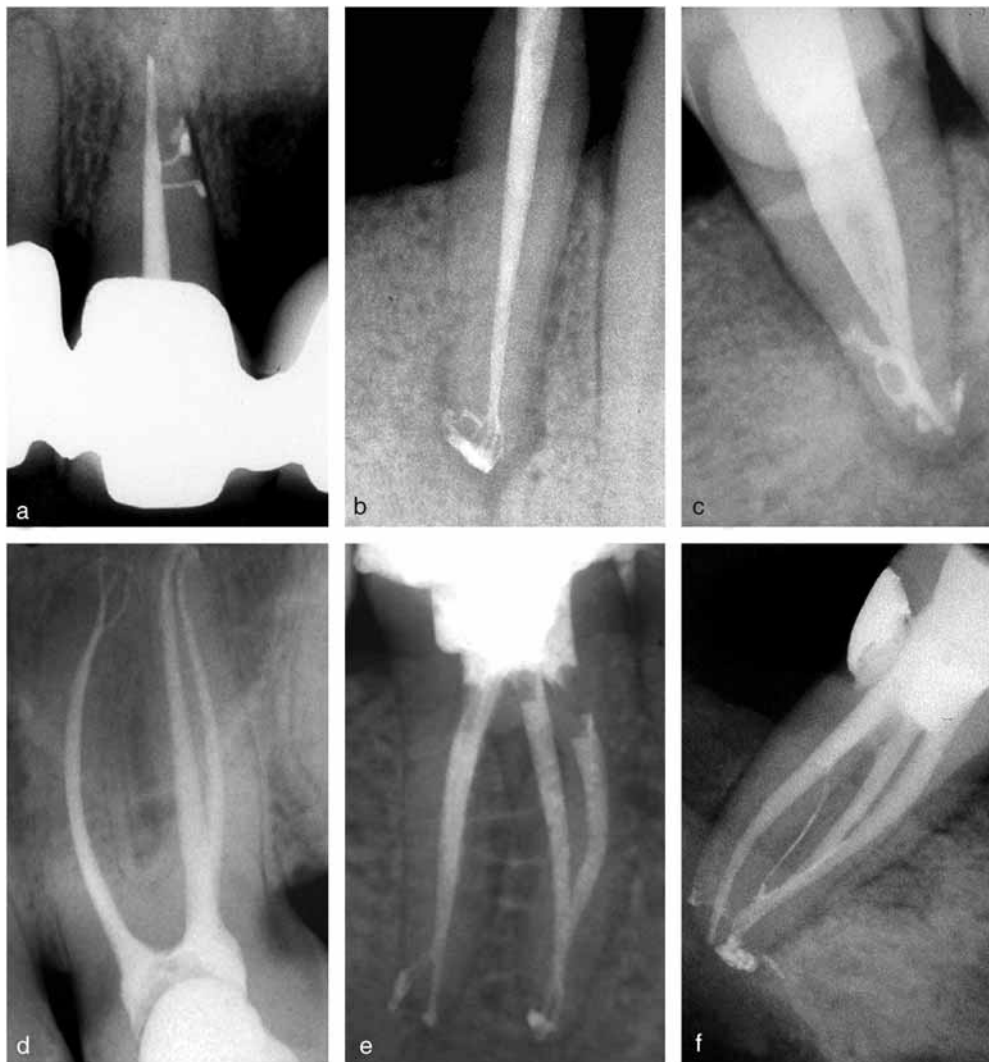

Fig. 18. Lateral ramifications of the main root canal in post-operative radiographs. (a) Maxillary incisor. (b) Mandibular incisor. (c) Mandibular second molar. (d) Maxillary first molar. (e, f) Two mandibular molars.

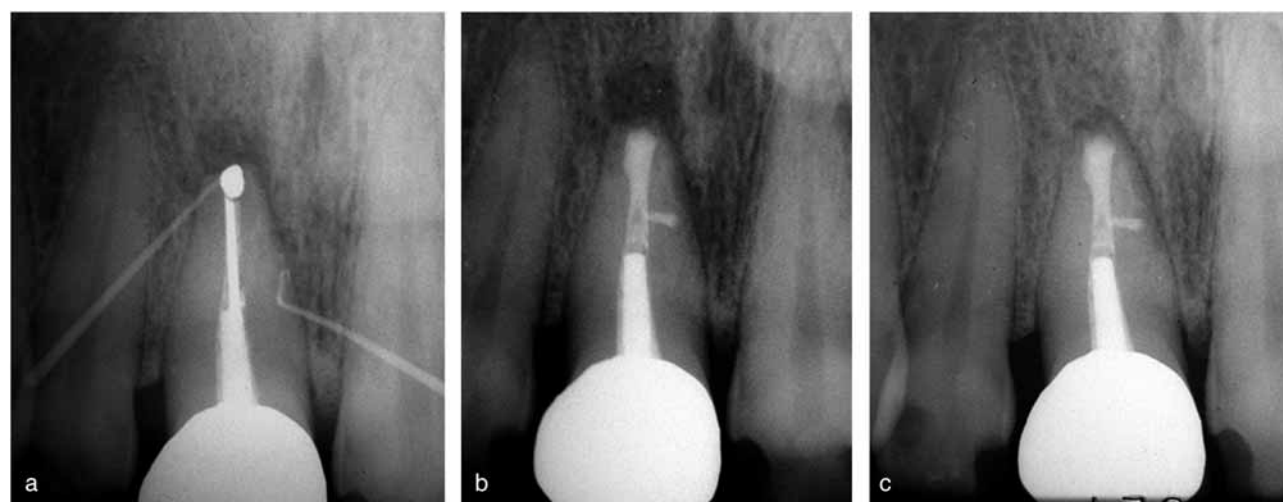
of accessory canals in 246 extracted teeth (445 root canals). All teeth were endodontically treated, filled with vertically condensed warm gutta-percha, and radiographed with a parallel technique. The examination of post-operative radiographs revealed lateral ramifications in 39.83% of the teeth (127). The frequency of lateral ramifications was significantly higher in maxillary premolars, followed by maxillary molars, mandibular molars, and mandibular premolars (Fig. 19a–f). The distribution of accessory canals in the three segments of the roots demonstrated the prevalence of lateral ramifications in the apical third of the root (84.5%) in comparison with the middle third (13.2%) and the coronal third (2.3%) of the root (127). Lateral ramifications of the main root canals contain pulp tissue that may be subjected to degenerative and necrotic processes. Several studies demonstrated that bacteria through the lateral ramification of the main root canal may cause periradicular and endo-perio pathosis, although the real impact of missed accessory canals on the outcome of endodontic treatment is not clear and remains controversial (128–132). The debridement of lateral ramifications cannot be accomplished mechanically; thus, it is dependent on the irrigating solutions and irrigation technique used. Irrigation procedures should be optimized to enhance removal of pulp debris and bacteria from accessory canals and isthmuses, thus improving the potential for their three-dimensional obturation. Recently, two studies (119, 120) demonstrated that 1-min irrigation

through an ultrasonically energized needle significantly enhances the cleanliness of the isthmuses in the mesial root of mandibular molars. Therefore, 1–2 min of ultrasonic irrigation should be recommended after chemo-mechanical preparation to improve the quality of debridement in the lateral ramifications of the root canal system (Fig. 20a–c).

## Prevention of missed anatomy

### Radiographic examination

Although periapical radiographs give a two-dimensional image of the three-dimensional root canal system, their interpretation reveals external and internal anatomic details that suggest the presence of extra canals and/or roots (133). A minimum of two diagnostic periapical radiographs should be taken for a careful evaluation of the root canal morphology using the parallel and mesial or distal horizontal angle techniques (134). The angled radiographs provide important information during root canal treatment. They help to visualize superimposed roots, allow good visualization of the buccal roots often covered by the palatal, displace the zygomatic process of the maxillary bone that can cover the apices of the molars, and suggest the position (buccal or lingual) of foreign bodies (134). Martinez-Lozano et al. examined the effect of X-ray tube inclination on accurately determin-



**Fig. 19.** Clinical impact of lateral canals. (a) Surgical re-treatment of a central incisor with two labial sinus tracts; the two gutta-percha cones reached periapical and latero-radicular radiolucency. (b) Post-operative radiographs showing the obturation with MTA of both the main and the lateral canals. (c) Two-year follow-up radiograph showing the healing of both radiolucencies.

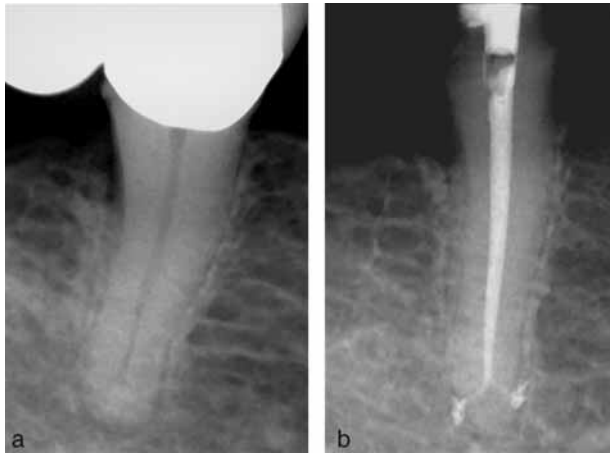


Fig. 20. (a) The sudden disappearance of the root canal pulp space in the pre-operative radiograph of a mandibular first premolar indicates a bi- or a tri-furcation. (b) Post-operative radiograph showing a deep apical bi-furcation.

ing the root canal system present in premolar teeth. They found that by varying the horizontal angle, the number of root canals observed in maxillary premolars coincided with the actual number of canals present (135). Pre-operative radiographs should be observed with careful attention; a sudden change in the radiographic density of the pulp space usually indicates an additional canal, whereas a sudden narrowing of or even disappearance of the root canal pulp space indicates a bi- or a tri-furcation (133) (Fig. 21a and b). In a case report of a mandibular molar with five canals, Friedman et al. (104) stated that the examination of pre-operative radiographs was of critical importance in identifying the complex canal morphology and ‘that any attempt to develop techniques that require fewer radiographs runs the risk of missing information which may be significant for the success of therapy’ (104). Post-operative radiographs can also provide valuable information on the presence and position of an extra root and/or canal; obturating material not centered within the root may be a sign of a missing canal. In an investigation on the clinical factors associated with non-surgical re-treatment, Hoen & Pink (136) observed a significant correlation in the asymmetric position of the previous obturation material and the subsequent ability to locate untreated canal space (136). Even though radiographs constitute an important aid during endodontic treatment, they can fail in diagnosing canal bi-furcations, accessory canals, and apical deltas. Nattress et al. (137) assessed the

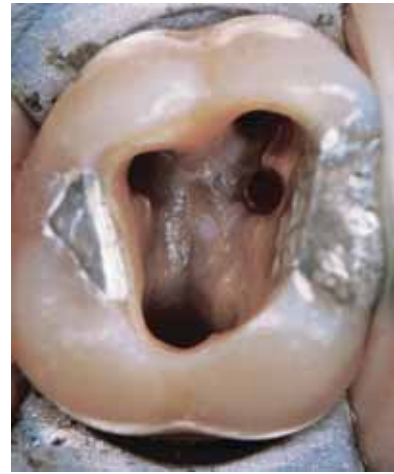

Fig. 21. Pulp chamber of a maxillary first molar demonstrating Krasner & Rankow's (38) law of color change and law of orifice location 1 and 2 (see text).

ability to detect the presence of canal bi-furcation in a root by viewing radiographs taken in the standard bucco-lingual direction. Using the guideline that ‘disappearance or narrowing of a canal infers division’ resulted in a failure to diagnose one-third of the twin canals.

Omer et al. (138) compared clearing and radiographic techniques in studying certain features of the root canal system; their results indicated the limited value of radiographs in detecting lateral canals, transverse anastomoses, and apical deltas. In another study, Bedford et al. (139) stated that plain radiographs were ‘insensitive in assessing the number of root canals present, the presence of lateral canals and the occurrence of canal obstructions.’ To summarize, information on root canal anatomy that comes from radiographs is valuable but incomplete, and should always be integrated with a careful clinical examination, preferably under magnification.

### Access opening

A correct pulp chamber opening represents the most important step in locating and negotiating the orifices of the root canals. An adequate opening should provide complete removal of the pulp chamber roof and all of the interferences to the root canal system such as dystrophic calcifications, dentinal neoformations, and restorations. A proper access cavity preparation requires good knowledge of pulp chamber anatomy and a careful study of the pre-operative radiographs. The use

of the operating microscope and endodontic probes such as the Hu-Friedy DG16 or the JW-17 (C K Dental Specialties) significantly facilitate the inspection of the pulp chamber floor and the discovery of canal orifices (38, 140, 141). The literature describing pulp chamber anatomy is generally based on photographs or designs of teeth with a complete crown and pulp chambers that are ideal for both position and width. Unfortunately, many clinical situations such as prosthetic crowns, large restorations, occlusal trauma, and dystrophic calcification can alter the original anatomy. Ideal access cavity designs in real teeth may lead to dangerous errors related to inadequate or over-aggressive preparations (38). The access cavity design should be adjusted to the anatomical and clinical situation of each tooth. In order to give clinicians reliable anatomical guides for access cavity preparation, in 2004, Krasner & Rankow evaluated the anatomy of 500 pulp chambers of extracted teeth and formulated the following anatomic laws (38):

1. The floor of the pulp chamber is always a darker color than the surrounding dentinal walls. This color difference creates a distinct junction where the walls and the floor of the pulp chamber meet (Law of color change).
2. The orifices of the root canals are always located at the junction of the walls and floor (Law of orifice location 1).
3. The orifices of the root canals are located at the angles in the floor-wall junction (Law of orifice location 2) (Fig. 22).
4. The orifices lay at the terminus of developmental root fusion lines, if present (Law of orifice location 3).

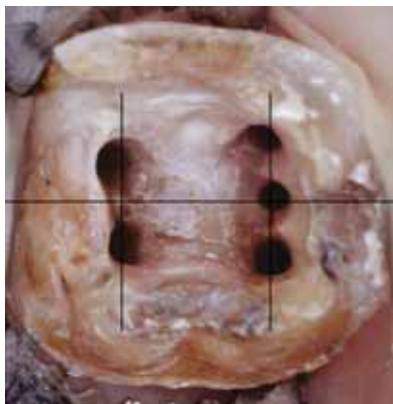

Fig. 22. Pulp chamber of a mandibular first molar demonstrating Krasner & Rankow's (38) law of symmetries 1 and 2 (see text).

5. The developmental root fusion lines are darker than the floor color.
6. Except for the maxillary molars, the orifices of the canals are equidistant from a line drawn in a mesial-distal direction through the pulp-chamber floor (Law of symmetry 1).
7. Except for the maxillary molars, the orifices of the canals lie on a line perpendicular to a line drawn in a mesial-distal direction across the center of the floor of the pulp chamber (Law of symmetry 2) (Fig. 23). The anatomical laws formulated by Krasner & Rankow (38) should be taken into consideration when opening pulp chambers because they give dentists general anatomical landmarks (independent from the crown anatomy) that may be very useful to localize the orifices of hidden canals.

### Use of the operating microscope

An important aid for locating root canals is the dental operating microscope (DOM), which was introduced into endodontics to provide enhanced lighting and visibility. It brings minute details into clear view. It enhances the dentist's ability to selectively remove dentin with great precision, thereby minimizing procedural errors. Several studies have shown that the DOM significantly increases the dentist's ability to locate and negotiate canals. Stropko (49) determined

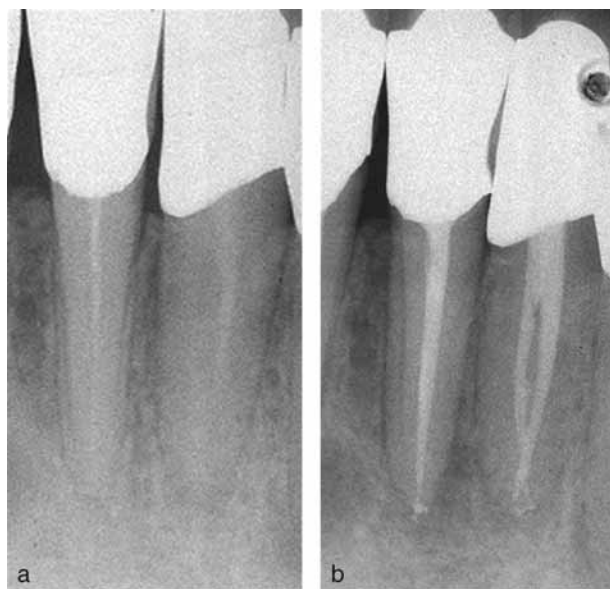


Fig. 23. Ultrasonic tips with sharp ends were used to localize the orifices of two separate canals in a mandibular lateral incisor. (a) Pre-operative radiograph. (b) Post-operative radiograph.



that a higher incidence of MB2 canals were located 'as he became more experienced, scheduled sufficient time for treatment, routinely used the DOM, and employed specific instruments adopted for micro-endodontics'. Kulild & Peters (142), utilizing the DOM, located two canals in the mesio-buccal root of maxillary molars 95.2% of the time. Baldassari-Cruz et al. (143) demonstrated an increase in the number of second mesio-buccal canals (MB2) located from 51% with the naked eye to 82% with the DOM. Schwarze et al. (144) identified 41.3% of MB2 canals using magnifying loupes and 93.7% of MB2 canals with the DOM. Buhrley et al. determined that the DOM was effective in locating MB2 canals of maxillary molars. When no magnification was used, this canal was located in only 18.2% of teeth. When using the DOM, the MB2 canal was found in 41 of 58 teeth or 71.1% (145). Yoshioka et al. confirmed the effectiveness of magnification and dentin removal (troughing) when locating the second mesio-buccal canal in 208 extracted maxillary molars (146). Liang et al. estimated the diagnostic potential of the DOM used for locating the MB2 orifice in 120 extracted maxillary first molars. The authors demonstrated that the sensitivity and accuracy of the DOM group were significantly higher than those of the naked eye group ( $P < 0.05$ ) (147). Coehlo de Carvalho & Zuolo concluded that the DOM made canal location easier by magnifying and illuminating the grooves in the pulpal floor and differentiating the color differences between the dentin of the floor and the walls. The DOM enabled them to find 7.8% more canals in mandibular molars (148). All of these studies demonstrate that magnification and illumination are essential armamentaria for performing proper endodontic therapy.

### **Use of ultrasonics**

Two different types of ultrasonic (US) units are commonly used in dentistry: magnetostrictive and piezoelectric. Piezoelectric units are generally preferred in Endodontics; they offer more cycles per second (40 kHz), generate less heat, and their inserts work in a linear, back-and-forth motion with a vibration amplitude that does not increase linearly with increasing generator power. Several brands of piezoelectric units are available today; all work properly when using tips designed and tuned for each specific generator (149–151). US tips for endodontic use provide important

advantages when refining access cavities, removing calcifications, and locating the orifices of hidden canals. US tips with thin, contra-angled, and parallel-sided profiles enhance access and vision while their abrasive coating improves the precision and cutting efficacy (149, 151). The best results are obtained when US tips are used with a light brush touch, medium power, and under the control of the operating microscope (152, 153). Yoshioka et al. determined that both magnification and dentin removal under magnification were effective in detecting the presence of MB2 canals. In particular, the authors could detect the MB2 canal in 7% of cases with the naked eye, in 18% of cases using magnification, and in 42% of cases using US tips under the operating microscope (146). Furthermore, the use of US instruments under magnification enhances the precision and reduces the risk of complications such as ledges and perforations (149, 151–153). US tips are available in different lengths, diameters, angles, and designs, with or without water ports. Ruddle (151) affirms that water port technology in non-surgical US instruments is contraindicated for four important reasons: (a) water decreases tip performance; (b) tips machined for internal water flow become more fragile; (c) there is an undesirable aerosol effect; and (d) water, in combination with dentinal dust, creates mud and reduced visibility, thereby increasing the potential for iatrogenic outcomes. However, using US tips in the pulp chamber without water produces dentinal dust, which accumulates on the floor and may hide the canal orifices. In addition, the risk of critical temperature increases on the root surface is significantly higher when US tips are used without a water coolant (154, 155). Thus, US tips with a water port are preferred; indeed, the intermittent use of the tips with and without water allows a proper cooling of the dentin and adjacent tissues without a significant loss of visibility (146, 154). When working with US instruments, it is important to select a tip with an adequate design to optimize efficiency while at the same time reducing the risk of complications such as tip breakage or perforation of the pulp chamber floor. Robust, slightly conical tips are indicated to refine the access cavity while thinner tips with rounded, non-aggressive ends are preferred when removing dentin from the orifice of MB2 or other hidden canals. The spherical end of these tips creates round grooves on the pulp chamber floor, which facilitate localization and negotiation of hidden canals. Conversely, thin US tips with sharp ends are

indicated to remove calcification from the pulp chamber and canal orifices, always under magnification (Fig. 10a and b). Lastly, abrasively coated US tips are preferred over stainless-steel tips when working in the pulp chamber because of their greater cutting efficiency (156, 157). Diamond-coated tips were, in particular, significantly more aggressive than stainless-steel and zirconium-nitride-coated tips in a study by Lin et al. (157); however, these tips did show a tendency to break. Niobium alloy tips, recently invented and patented by Satelec, appear to be a promising material for US tips due to their biocompatibility, resistance, and transmission of ultrasound. Clinically, the tips are efficient and do not break but there are currently no studies available that demonstrate their superiority over the stainless-steel or diamond-coated tips.

### Impact of missed anatomy on the outcome of endodontic treatments

It is generally accepted that a major cause for the failure of root canal therapy is an inability to recognize the presence of and to adequately treat all of the canals (4, 5, 11). Unfortunately, prospective studies demonstrating the impact of missed anatomy on outcome of endodontic treatment are not available for obvious ethical reasons; researchers could not in good conscience neglect to treat a known MB2 for the sake of an experimental group with which to compare (11). Therefore, the endodontic literature on this issue consists mainly of retrospective and epidemiological studies. The more extensive and classic of these studies is the Washington study, which was conducted at the University of Washington, revealing an almost 9% failure rate 2 years after treatment (5). In the Washington study, unfilled canals were associated with 3% of endodontic failures, whereas incomplete obturations and excessive overfills were noted in 59% and 4% of the failures, respectively (5). In a statistical analysis of re-treatment cases, Allen et al. analyzed a total of 1300 endodontic patients for factors that may have contributed to the failure of the original treatment or the success of the re-treatment (158). The reasons for re-treatment were judged from patient records and radiographs and were divided into seven categories; untreated canals, in this study, were responsible for failure in 114 cases, with an 8.8% prevalence (158). In another investigation, Hoen & Pink determined

radiographical and clinical factors associated with contemporary non-surgical endodontic re-treatment (136). Approximately 1100 failing endodontically treated teeth were screened and 337 consecutive re-treatment cases were evaluated and treated. The vast majority of the retreated cases involved multiple factors. Eighty-five percent of the cases presented with periradicular radiolucencies. There were 53 cases in which the previous obturation material was not symmetrically located within the root (22% of the cases measured). In 47 out of 53 cases with an asymmetrical obturation, an additional canal was located during the clinical non-surgical re-treatment (89%). The association of asymmetric obturations and clinically locating additional canal space was statistically significant (Chi-square,  $P \leq 0.05$ ). The incidence of missed roots or canals discovered in this investigation was 42% (136). The different incidence of untreated canals reported in Hoen's and Allen's studies may depend on the different methods used in the two investigations. Allen et al. (158) based the identification of missed canals mainly on post-operative radiographs, whereas Hoen & Pink completed all clinical evaluations under a magnification of at least 3.25 power (136).

A group of epidemiological surveys supports the impact of missed canals on endodontic failures, demonstrating a direct link between the complexity of the root canal system and the incidence of post-treatment disease. In the Washington study (5), the mandibular first premolar had the highest failure rate at 11.45%. Possible reasons for this conclusion are the numerous variations in root canal morphology that mandibular premolars may have and the difficult access to additional canal systems when present (5). De Moor et al. (159) collected data from 206 panoramic radiographs to assess the technical standard of root canal treatment in a Belgian population as well as the prevalence of AP. The distribution of teeth with periapical pathosis seen on panoramic radiographs according to the tooth type demonstrated that mandibular first molars showed a 17.3% incidence of AP, whereas for mandibular central incisors the prevalence was 2.1%. For maxillary first premolars, the frequency of periapical pathosis was 11.9%, whereas for the maxillary central incisor, it was 5.2% (159). In another similar epidemiological survey in an adult French population, Lupi-Pegurier et al. (160) reported a frequency of periapical radiolucencies in maxillary molars and premolars of 14.8% and 11.3%, respectively,

whereas the prevalence was 5.7% in maxillary incisors. Two additional retrospective analyses of orthopantomograms confirmed that posterior root-filled teeth (premolars and molars) had a greater frequency of AP compared with anterior root-filled teeth (161, 162). Loftus et al. (161), in an adult Irish population, reported an incidence of AP of 31.7% in molars and 20.7% in anterior teeth. Kabak & Abbott (162), in an adult Belarusian population, reported a 23% incidence of AP in molars, 14% in premolars, 4% in canines, and 6% in incisors. To summarize, teeth with frequent aberrant canal configurations present a higher risk of developing post-treatment disease.

A new approach for the study of the impact of missed anatomy on the outcome of non-surgical root canal treatment has been described by Wolcott et al. in two clinical investigations of MB2 canals in endodontically treated and retreated maxillary molars (10, 11). The authors researched the difference between the incidence of MB2 canals in maxillary molars in need of initial treatment versus failing maxillary molars that were in need of re-treatment. The incidence of an MB2 canal in first molar re-treatments was 67% compared with a 59% incidence rate in initial treatments (11). The significant difference in the incidence of MB2 canals between initial treatment and re-treatment cases suggests that failure to find and treat existing MB2 canals will decrease the long-term prognosis. Hopefully, the methodology used in the two Wolcott studies will be extended to other categories of teeth in future investigations; by comparing the number of canals found in failed treatment cases and after re-treatment, it will be possible to evaluate the impact of untreated canals on clinical outcome.

## **Clinical impact of missed anatomy**

The clinical impact of untreated canal spaces may vary from clinical and radiographical normalcy to severe symptoms of acute pulpitis or apical abscess. The following case reports provide an idea of the extreme variability of symptomatology associated with missed canal spaces.

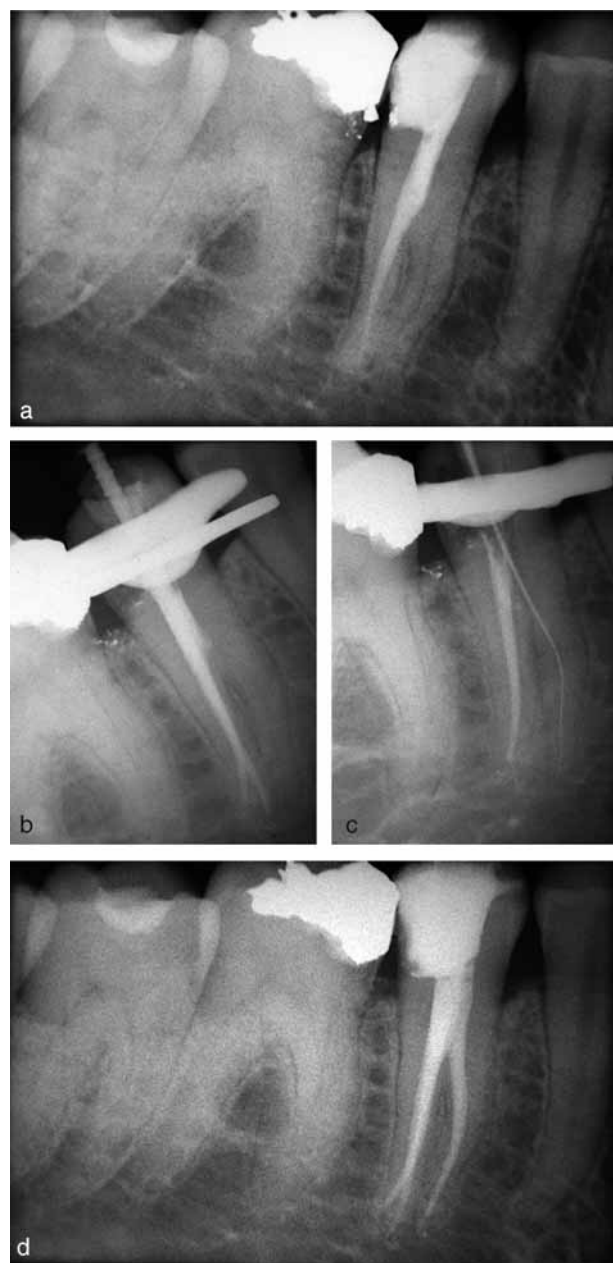
### **Case report 1**

A 40-year-old male patient was referred to our clinic for evaluation and re-treatment of tooth #29. The patient stated that after the previous endodontic treatment

about 6 months earlier, he had experienced moderate pain that was tolerable; however, for the past 3 days, the pain characteristics had changed to severe spontaneous pain, exaggerated by hot stimuli. Clinical examination revealed moderate sensitivity to percussion of the tooth. Examination of the buccal mucosa and periodontal probing were normal. Radiographic examination revealed a double-rooted tooth, with only one of the roots (distal) endodontically treated. Furthermore, the asymmetry of obturation material within the distal root suggested the presence of a third root or canal. No periapical radiolucency was evident (Fig. 24a). Under magnification, the old obturation material was removed and a second disto-lingual canal orifice was located in the middle third of the root. Then, the two distal canals were shaped and filled with two Thermafil<sup>®</sup> obturators (Dentsply Maillefer) (Fig. 24b). Following the indications of the post-operative radiograph, US tips were used to remove calcified dentin from the pulp chamber, thus locating the orifice of the mesial canal, which was shaped and filled in the same visit. Pulp tissue in the mesial canal was still vital (Fig. 24c and d). The tooth, examined clinically after one week, was totally asymptomatic.

### **Case report 2**

A 50-year-old male patient was referred to our clinic for evaluation and surgical re-treatment of tooth #20. The patient indicated that the tooth had been endodontically treated 3 years earlier and was restored with a metal cast post and a metal ceramic bridge (Fig. 25a). After the treatment, the patient experienced two episodes of acute apical abscess. Clinical examination revealed palpation pain associated with the buccal mucosa of tooth #20 and severe tenderness to percussion. Examination of the pre-operative radiograph revealed an incongruous endodontic treatment, which did not reach the apex, and a large periapical lesion. The radiographic appearance of the tooth did not clearly show the presence of extra roots and/or canals (Fig. 25a). After local anesthesia (2% lidocaine with 1:50 000 epinephrine), a mucoperiosteal flap was made. Periapical pathosis was noted at the apex of tooth #20 with cortical bone fenestration. The granulation tissue was curetted, an osteotomy was prepared, and 3 mm of the root ends was resected with the aid of a surgical operating microscope. The resected root surfaces were examined at a high magnification.



**Fig. 24.** Case report 1. (a) Pre-operative radiograph. (b) Obturation of the two distal canals. (c) Working length of the mesial canal. (d) Post-operative radiograph.

Methylene blue staining revealed two previously unidentified apical orifices and microleakage of the previously obturated root canal (Fig. 25b). Root-end preparation was carried out with ProUltra Surgery tips (Dentsply Maillefer) under the microscope and the prepared cavities were filled with MTA (Dentsply Maillefer) (Fig. 25c). Post-operative radiographs were taken (Fig. 25d). The patient was examined clinically and radiographically at a 1-year recall visit. The tooth

was asymptomatic and periapical healing was observed radiographically (Fig. 25e).

### Case report 3

A 15-year-old female patient was referred to our clinic for evaluation and non-surgical re-treatment of tooth #3. The tooth had already been endodontically treated two times. The patient reported moderate pain during mastication, but no spontaneous pain was present. Clinical examination revealed a buccal sinus tract stoma in the attached gingiva between the second premolar and the first molar (Fig. 26a). The patient was sensitive to percussion only on tooth #3; vitality tests on tooth #3 were negative. There was no mobility, but probing revealed a broad periodontal pocketing in the mesio-buccal surface of the mesial root of the first molar with a maximum depth of 7 mm. The surrounding teeth did not demonstrate any clinical signs or symptoms. Radiographic examination with a gutta-percha cone within the sinus tract confirmed that the origin of the infection was the mesio-buccal root of the first molar. The asymmetry of the obturation material within the MB root suggested the presence of an untreated canal. A small radiolucency surrounded the apex of the mesio-buccal root, whereas the disto-buccal and palatal roots did not show radiographic signs of infection (Fig. 26a). Because of the poor coronal restoration with a high risk of coronal microleakage, we decided to retreat all canals. First, a correct access cavity was opened and the old obturation material was removed from the three main canals MB1, DB, and palatal. The three canals were abundantly irrigated with sodium hypochlorite. The observation of the pulp chamber floor under the operating microscope did not reveal any sign of the MB2 canal (Fig. 26b). Using a US tip, we created a groove between the orifices of the MB1 and the palatal canals. After that, the second mesio-buccal canal could be localized using a DG 16 endodontic probe and then negotiated and shaped (Fig. 26c and d). Next, the reshaping of the three main canals was completed (Fig. 26e) and the four canals were obturated with vertically condensed warm gutta-percha (Fig. 26f and g). At the 1-week recall visit, the patient was symptom-free and the sinus tract had healed. A 1-year follow-up radiograph demonstrated complete healing of the bone lesion (Fig. 26h).

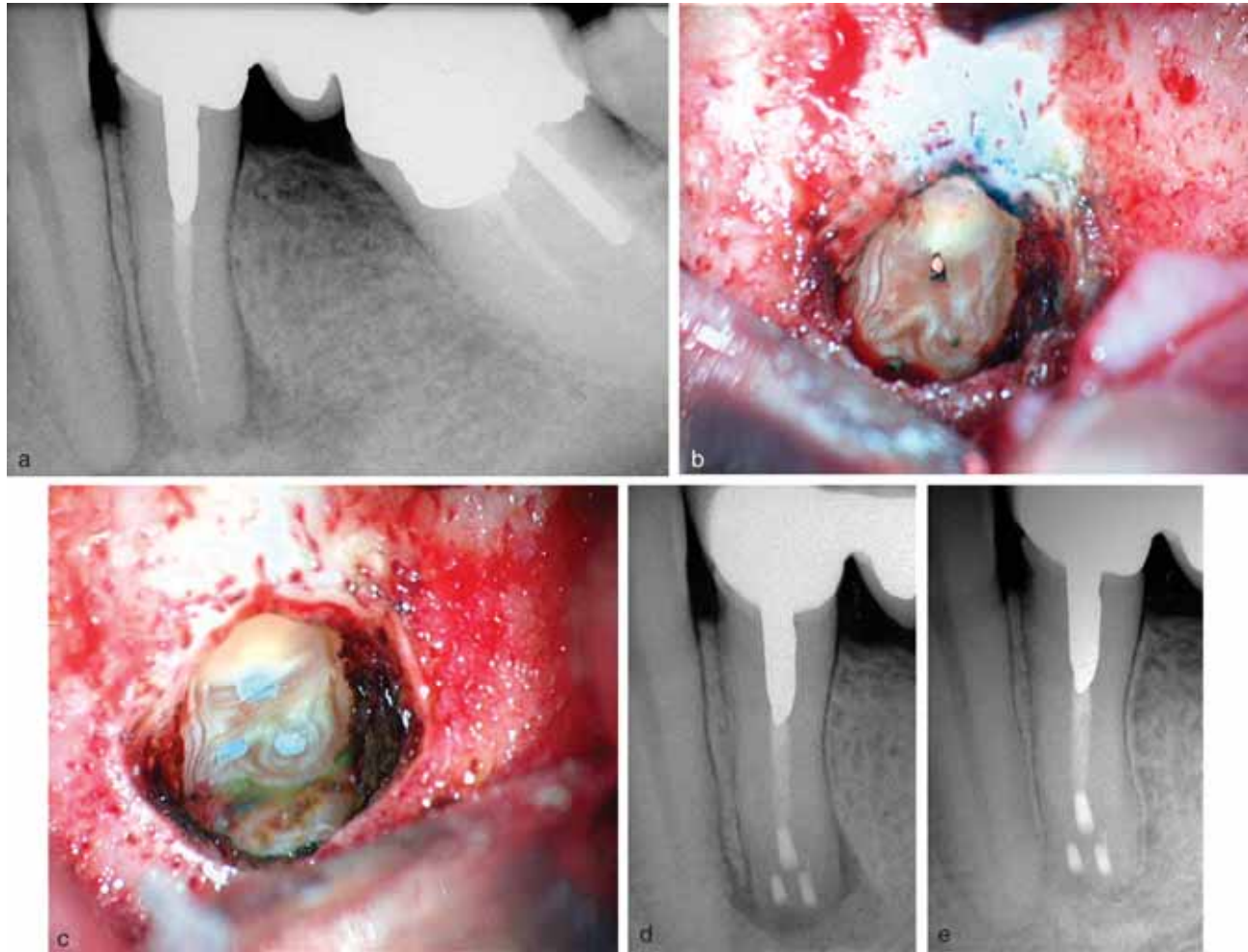


Fig. 25. Case report 2. (a) Pre-operative radiograph. (b, c) Intra-operative photographs. (d) Post-operative radiograph. (e) 1-year follow-up radiograph.

#### Case report 4

A 48-year-old male patient was referred to our clinic by a dentist who had endodontically treated the maxillary right first molar 1 year earlier. The dentist localized and treated three canals (MB1, DB, and palatal), restored the tooth with composite resin, and covered it with a ceramic-metal crown. After the initial treatment, the patient experienced moderate sensitivity to pressure that was tolerable; however, 3 months later, pain characteristics had changed to intense pain with severe swelling. Therefore, the patient returned to his dentist, who made a diagnosis of acute apical abscess, prescribed antibiotics, removed the crown, re-opened the tooth, and attempted root canal re-treatment, which resulted in a perforation on the pulp chamber floor (Fig. 27a). Consequently, the dentist decided to refer the patient to us for evaluation and treatment.

Clinical examination showed moderate swelling of the buccal mucosa and severe tenderness to percussion of the tooth #3, whereas responses to cold and hot stimuli were negative. Periodontal examination revealed probing depths of 4–6 mm, with moderate probing into the furcation. A pre-operative radiograph taken after removing the prosthetic crown revealed normalcy of the palatal and DB roots, whereas the MB root showed an apparent radiolucency around the apex. The asymmetry of the obturation material within the MB root profile confirmed the suspicion of an untreated, missed canal (Fig. 27a). The observation of the pulp chamber floor under the operating microscope revealed an additional canal orifice partially hidden by dentin and by the composite resin used to restore the tooth after the first treatment. A perforation with a diameter of 3–4 mm was present between the MB1 and the palatal canals (Fig. 27b). Using an

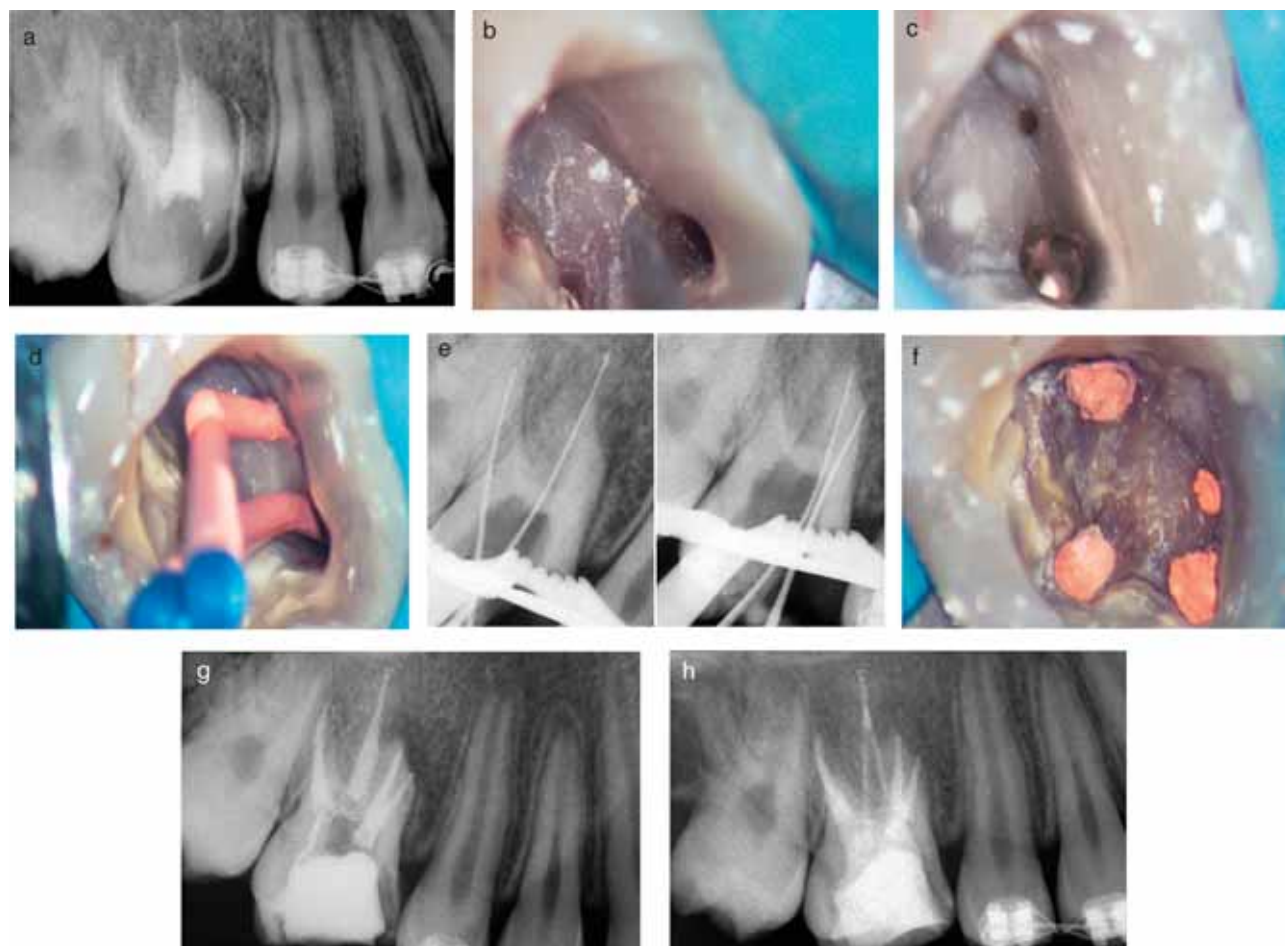

Fig. 26. Case report 3. (a) Pre-operative radiograph. (b–d) Intra-operative photographs. (e) Working length radiographs. (f) Post-operative photograph. (g) Post-op radiograph. (h) One-year follow-up radiograph.

US tip under magnification, the interferences which hid the MB2 orifice were removed and the canal was then negotiated and shaped. The MB1 canal was also retreated and a working length radiograph was taken to confirm that the two canals had separate apical foramina (Fig. 27c and d). Next, the two MB canals were filled with vertically condensed warm gutta-percha and the perforation was repaired with MTA. To increase the stability of the MTA layer, we decided to create additional retention within the orifice of the MB2 canal (Fig. 27e). A post-operative radiograph was then taken to control both the obturation of the two MB canals and the repair of the perforation (Fig. 27f). Two weeks after the therapy, the tooth was asymptomatic and the swelling had disappeared. The patient was examined clinically and radiographically at a 1-year recall visit, at which time the tooth was asymptomatic and the periapical lesion had healed (Fig. 27g).

### Case report 5

A 22-year-old male visited our clinic for clinical evaluation and re-treatment of tooth #30. The patient stated that after the first endodontic treatment, 2 years earlier, he had experienced moderate pain during mastication exaggerated by hot stimuli. After some weeks, heat sensitivity disappeared; however, tooth #30 remained sensitive to contact with the opposing teeth during mastication. Clinically, at the evaluation appointment, the tooth had a large coronal composite restoration, was sensitive to palpation and percussion, and did not respond to the pulp vitality tests (Fig. 28a). The periodontal condition of the tooth was normal and no pocketing was observed. Also, tooth mobility was normal without any observable swelling. Radiographic examination confirmed that the tooth had been previously endodontically treated. Under the crown restoration, severe secondary caries and a screw post in

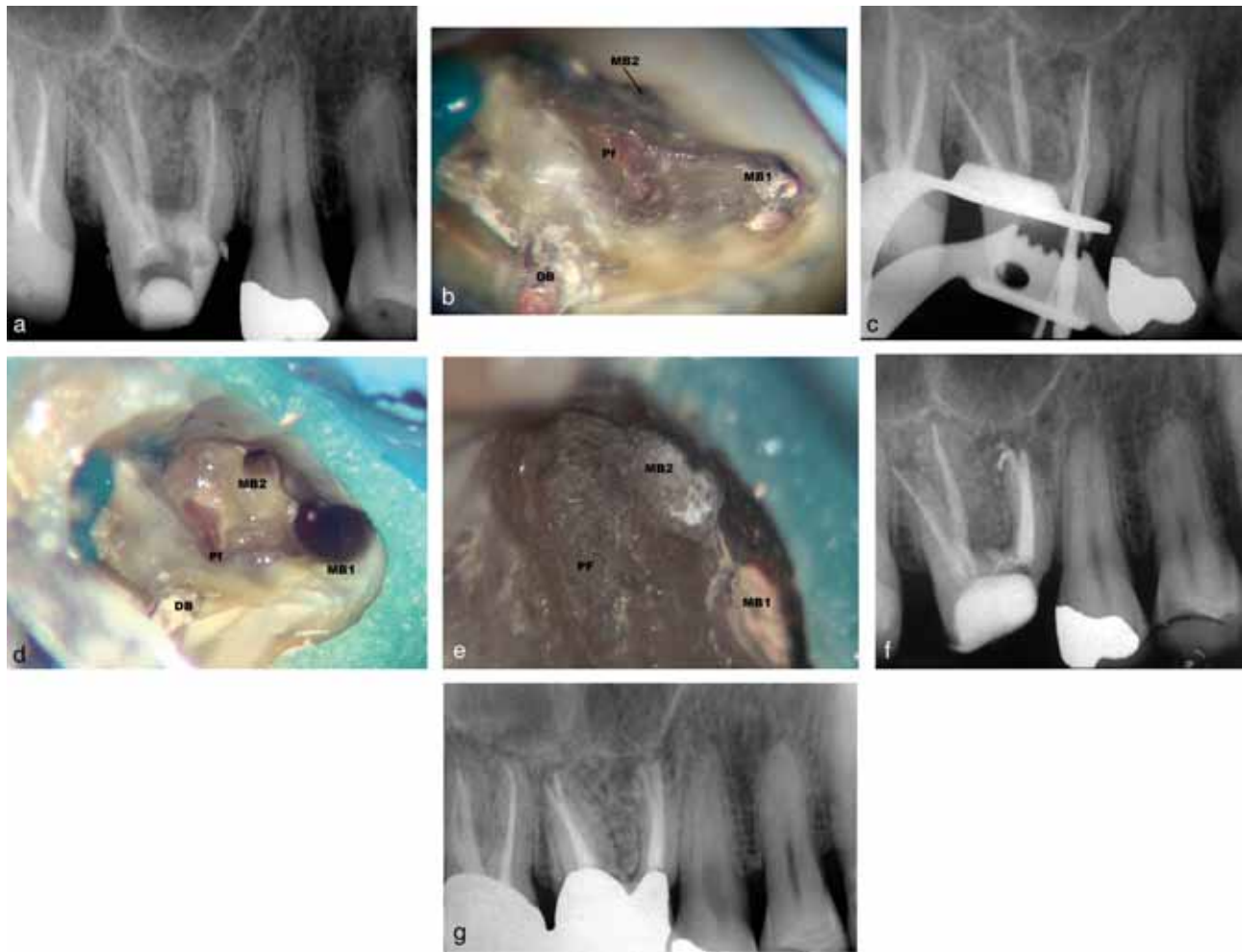


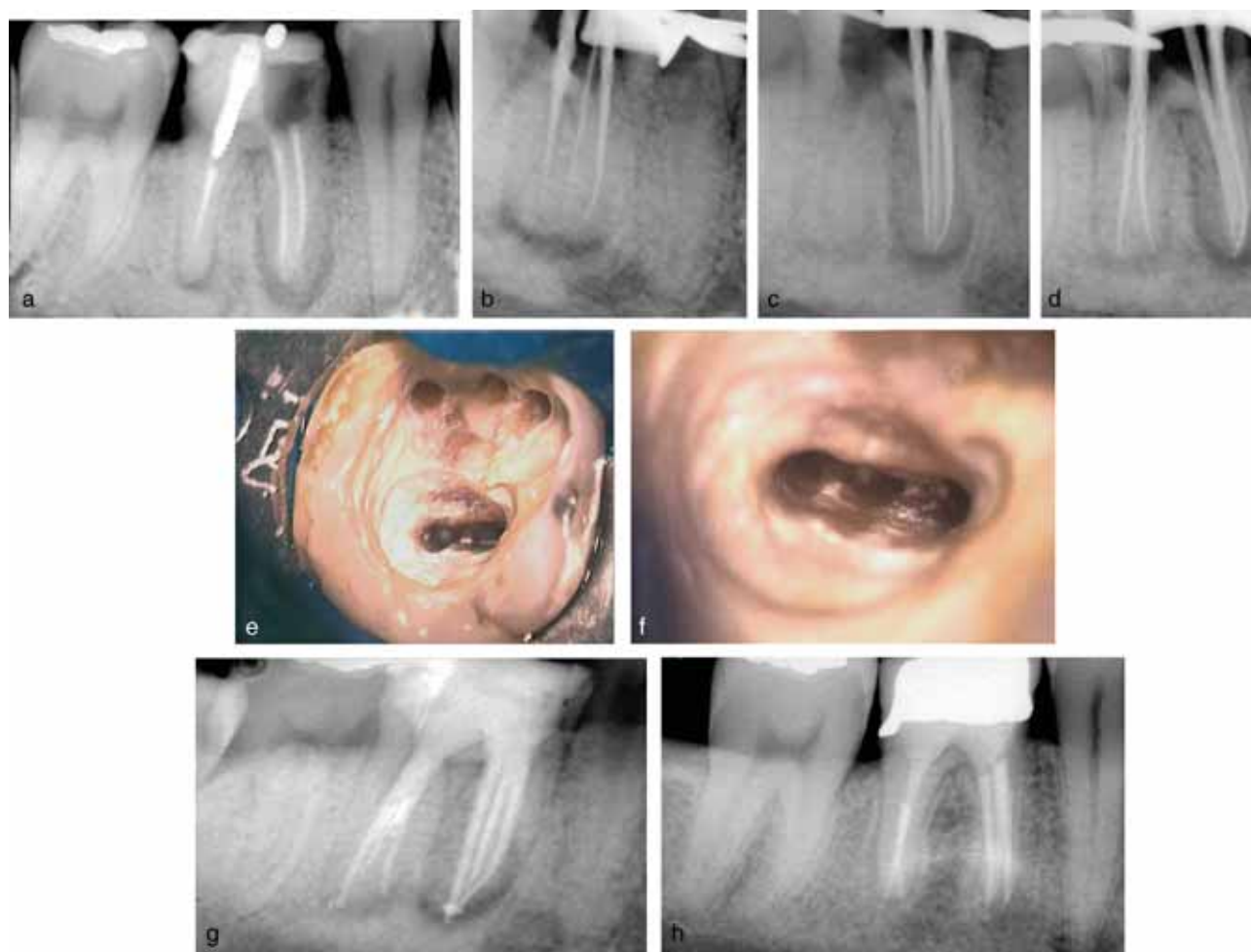Fig. 27. Case report 4 (Pf = perforation). (a) Pre-operative radiograph. (b) Pre-operative photograph. (c) Working length radiograph. (d, e) Intra-operative photographs. (f) Post-operative radiograph. (g) One-year follow-up radiograph.

the distal root were evident. The root canal obturation stopped at the middle third of the canal in the distal root and in the apical third in the mesial canals; both root apices were surrounded by periradicular radiolucencies (Fig. 28a). Under magnification, the post, the carious dentin, and all of the old obturation material were removed, the root canals were abundantly irrigated with sodium hypochlorite, and the pulp chamber floor was examined with the help of a DG 16 endodontic probe. Increasing the magnification of the operating microscope to  $\times 20$ , it was possible to locate the orifice of a third mesial canal and a trifurcation in the distal root starting in the middle third (Fig. 28b–f). US tips were used to remove all dentin interferences to the canal orifices. The three mesial canals were separate, whereas the middle distal canal merged with the disto-lingual canal (Fig. 28b–f). All

canals were then shaped, disinfected, and filled with vertically condensed warm gutta-percha. The post-operative radiograph taken with the shift cone angle technique demonstrated the presence of the six canals (Fig. 28g). At the following visit, one week after the re-treatment, the tooth was asymptomatic. The 1-year, 2-year, 3-year, and 5-year follow-up radiographs demonstrated complete healing of the osseous lesions with evidence of periodontal ligament formation around both roots (Fig. 28h).

### Concluding remarks

The risk of missing anatomy during root canal treatments is high due to the complexity of the root canal system. All categories of teeth may have extra



**Fig. 28.** Case report 5. (a) Pre-operative radiograph. (b, c) Intra-operative radiographs of the three separate mesial canals. (d) Intra-operative radiograph of the two main distal canals. (e) Intra-operative photographs of the three mesial canals. (f) Intra-operative photograph of the three distal canals. (g) Post-operative radiograph. (h) 5-year follow-up radiograph.

roots and/or canals, with an increased likelihood of finding aberrant canal configurations in premolars and molars. In addition, lateral ramifications of the root canal system may be present in all teeth with significant frequency, increasing the probability of leaving untreated spaces after root canal therapy. Prevention of missed anatomy starts with good pre-operative radiographs, even though radiographs have limitations in assessing the number of canals and the presence of accessory canals and anastomoses. Without doubt, a proper access cavity preparation is of central importance in localizing the orifices of the root canals. In addition, to find hidden and extra canals, an adequate armamentarium is required; the DOM will provide enhanced lighting and visibility, whereas US tips will allow a controlled and delicate removal of calcifications and other interferences to the canal orifices. The

impact of missed anatomy on the outcome of endodontic treatment is difficult to assess and the literature on this subject is limited; a promising approach for future investigation may involve a comparison of the number of canals found in failed treatment cases and after re-treatment. The clinical impact of missed anatomy can be clearly demonstrated with the large number of re-treatment case reports available in the literature; in the majority of these cases, failure of endodontic therapy is associated with untreated canal space. Localization and treatment of the missed anatomy typically leads to complete clinical and radiographic healing. Finally, untreated canal space may be associated with a remarkable variety of symptoms ranging from asymptomatic teeth to acute responses to hot and cold stimuli and from slight sensitivity to percussion and/or palpation to acute



abscesses. The variability of symptoms and diagnostic and therapeutic difficulties make the treatment of missed anatomy a challenge for the general dentist; consequently, treatment of these difficult cases should be managed by dentists with advanced training in endodontics.

## References

1. Ørstavik D. Time-course and risk analyses of the development and healing of chronic apical periodontitis in man. *Int Endod J* 1996; **29**: 150–155.
2. Friedman S. Considerations and concepts of case selection in the management of post-treatment endodontic disease (treatment failure). *Endod Topics* 2002; **1**: 54–78.
3. Kirkevang LL, Horsted-Bindslev P. Technical aspects of treatment in relation to treatment outcome. *Endod Topics* 2002; **2**: 89–102.
4. Vertucci FJ. Root canal morphology and its relationship to endodontic procedures. *Endod Topics* 2005; **10**: 3–29.
5. Ingle JL, Beveridge EE, Glick DH, Weichman JA. Modern endodontic therapy. In: Ingle JL, Bakland LK, eds. *Endodontics*, 4th Edn. Baltimore, MA: Williams and Wilkins, 1994: 27–53.
6. Weine FS, Healey NJ, Gerstein H, Evanson L. Canal configuration in the mesiobuccal root of the maxillary first molar and its endodontic significance. *Oral Surg Oral Med Oral Pathol* 1969; **28**: 419–425.
7. Cheung GS. Endodontic failures – changing the approach. *Int Dent J* 1996; **46**: 131–138.
8. Neaverth EJ, Kotler LM, Kaltenbach RF. Clinical investigation (*in vivo*) of endodontically treated maxillary first molars. *J Endod* 1987; **13**: 506–512.
9. Vertucci FJ. Root canal anatomy of the human permanent teeth. *Oral Surg Oral Med Oral Pathol Oral Radiol Endod* 1984; **58**: 589–599.
10. Wolcott J, Ishley D, Kennedy W, Johnson S, Minnich S. Clinical investigation of second mesiobuccal canals in endodontically treated and retreated maxillary molars. *J Endod* 2002; **28**: 477–479.
11. Wolcott J, Ishley D, Kennedy W, Johnson S, Minnich S, Meyers J. A 5 yr clinical investigation of second mesiobuccal canals in endodontically treated and retreated maxillary molars. *J Endod* 2005; **31**: 262–264.
12. Sert S, Bayirli GS. Evaluation of the root canal configurations of the mandibular and maxillary permanent teeth by gender in the Turkish population. *J Endod* 2005; **30**: 391–399.
13. Caliskan MK, Pehlivan Y, Sepetcioglu F, Turkun M, Tuncer SS. Root canal morphology of human permanent teeth in a Turkish population. *J Endod* 1995; **21**: 200–204.
14. Thompson BH, Portell FR, Hartwell GR. Two root canals in a maxillary lateral incisor. *J Endod* 1985; **11**: 353–355.
15. Todd HW. Maxillary right central incisor with two root canals. *J Endod* 1976; **2**: 227.
16. van der Vyver PJ, Traub AJ. Maxillary central incisor with two root canals: a case report. *J Dent Assoc S Afr* 1995; **50**: 132–133.
17. Cabo-Valle M, Gonzalez-Gonzalez JM. Maxillary central incisor with two root canals: an unusual presentation. *J Oral Rehabil* 2001; **28**: 797.
18. Pecora JD, Santana SVS. Maxillary lateral incisor with two roots – case report. *Braz Dent J* 1991; **2**: 151–153.
19. Fabra-Campos H. Upper lateral incisor with 2 canals. *Endodontics* 1991; **9**: 104–108.
20. Todd HW. Maxillary right central incisor with two root canals. *J Endod* 1976; **2**: 227–231.
21. Genovese FR, Marsico EM. Maxillary central incisor with two roots: a case report. *J Endod* 2003; **29**: 220–221.
22. Sinai IH, Lustbader S. A dual-rooted maxillary central incisor. *J Endod* 1984; **10**: 105–106.
23. Mader CL, Konzelman JL. Double-rooted maxillary central incisors. *Oral Surg Oral Med Oral Pathol Oral Radiol Endod* 1980; **50**: 99.
24. Sponchiado CS, Ismail H, Lima Braga MR, de Carvalho F, Simões C. Maxillary central incisor with two root canals: a case report. *J Endod* 2006; **32**: 1002–1004.
25. Benenati FW. Endodontic treatment of a maxillary central incisor with two separate roots: case report. *Gen Dent* 2006; **54**: 265–266.
26. Thompson BH, Portell FR, Hartwell GR. Two root canals in a maxillary lateral incisor. *J Endod* 1985; **11**: 353–355.
27. Christie WH, Peikoff MD, Acheson DW. Endodontic treatment of two maxillary lateral incisors with anomalous root formation. *J Endod* 1981; **7**: 528–534.
28. Collins IJ. Maxillary lateral incisor with two roots. *Aust Endod J* 2001; **27**: 37–38.
29. Drent T, de Baat C. A two-rooted maxillary incisor. *Ned Tijdschr Tandheelkd* 2006; **113**: 33–35.
30. Walvekar SV, Behbehani JM. Three root canals and dens formation in a maxillary lateral incisor: a case report. *J Endod* 1997; **23**: 185–186.
31. Mangani F, Ruddle CJ. Endodontic treatment of a “very particular” maxillary central incisor. *J Endod* 1994; **20**: 560–561.
32. Pecora JD, Saquy PC, Sousa Neto MD, Woelfel JB. Root form and canal anatomy of maxillary first premolars. *Braz Dent J* 1992; **2**: 87–94.
33. Soares JA, Leonardo RT. Root canal treatment of three-rooted maxillary first and second premolars – a case report. *Int Endod J* 2003; **36**: 705–710.
34. Goon WWY. The “radiculous” maxillary premolar: recognition, diagnosis and case report of surgical intervention. *Northwest Dent* 1993; **72**: 31–33.
35. Barkhordar RA, Sapone J. Surgical treatment of a three-rooted maxillary second premolar: report of a case. *Oral Surg Oral Med Oral Pathol Oral Radiol Endod* 1987; **63**: 614–616.

36. Ferreira CM, de Moraes IG, Bernardineli N. Three-rooted maxillary second premolar. *J Endod* 2000; **26**: 105–106.
37. Low D. Unusual maxillary second premolar morphology: a case report. *Quint Int* 2001; **32**: 626–628.
38. Krasner P, Rankow HJ. Anatomy of the pulp chamber floor. *J Endod* 2004; **30**: 5–16.
39. Sardar KP, Khokhar NH, Siddiqui MI. Frequency of two canals in maxillary second premolar tooth. *J Coll Physicians Surg Pak* 2007; **17**: 12–14.
40. Sieraski SM, Taylor GT, Kohn RA. Identification and endodontic management of three-canal maxillary premolars. *J Endod* 1985; **15**: 29–32.
41. Cleghorn BM, Christie WH, Dong CCS. Root and root canal morphology of the human permanent maxillary first molar: a literature review. *J Endod* 2006; **32**: 813–821.
42. Brown P, Herbranson E. *Dental Anatomy and 3D Tooth Atlas, Version 2.0*, 2nd Edn. Illinois: Quintessence, 2004.
43. Weine FS, Hayami S, Hata G, Toda T. Canal configuration of the mesiobuccal root of the maxillary first molar of a Japanese sub-population. *Int Endod J* 1999; **32**: 79–87.
44. Pineda F. Roentgenographic investigation of the mesiobuccal root of the maxillary first molar. *Oral Surg Oral Med Oral Pathol* 1973; **36**: 253–260.
45. Neaverth EJ, Kotler LM, Kaltenbach RF. Clinical investigation (*in vivo*) of endodontically treated maxillary first molars. *J Endod* 1987; **13**: 506–512.
46. Ross IF, Evanchik PA. Root fusion in molars: incidence and sex linkage. *J Periodontol* 1981; **52**: 663–667.
47. Alavi AM, Opananon A, Ng YL, Gulabivala K. Root and canal morphology of Thai maxillary molars. *Int Endod J* 2002; **35**: 478–485.
48. Nosonowitz DM, Brenner MR. The major canals of the mesiobuccal root of the maxillary 1st and 2nd molars. *N Y J Dent* 1973; **43**: 12–15.
49. Stropko JJ. Canal morphology of maxillary molars: clinical observations of canal configurations. *J Endod* 1999; **25**: 446–450.
50. Seidberg BH, Altman M, Guttuso J, Suson M. Frequency of two mesiobuccal root canals in maxillary permanent first molars. *J Am Dent Assoc* 1973; **87**: 852–856.
51. Fogel HM, Peikoff MD, Christie WH. Canal configuration in the mesiobuccal root of the maxillary first molar: a clinical study. *J Endod* 1994; **20**: 135–137.
52. De Moor RJG. C-shaped root canal configuration in maxillary first molars. *Int Endod J* 2002; **35**: 200–208.
53. Stone LH, Stroner WF. Maxillary molars demonstrating more than one palatal root canal. *Oral Surg Oral Med Oral Pathol* 1981; **51**: 649–652.
54. Hülsmann M. A maxillary first molar with two distobuccal root canals. *J Endod* 1997; **23**: 707–708.
55. Baratto-Filho F, Fariniuk LF, Ferreira EL, Pecora JD, Cruz-Filho AM, Sousa-Neto MD. Clinical and macroscopic study of maxillary molars with two palatal roots. *Int Endod J* 2002; **35**: 796–801.
56. Barbizam JV, Ribeiro RG, Tanomaru Filho M. Unusual anatomy of permanent maxillary molars. *J Endod* 2004; **30**: 668–671.
57. Thews ME, Kemp WB, Jones CR. Aberrations in palatal root and root canal morphology of two maxillary first molars. *J Endod* 1979; **5**: 94–96.
58. Stone LH, Stroner WF. Maxillary molars demonstrating more than one palatal root canal. *Oral Surg Oral Med Oral Pathol* 1981; **51**: 649–652.
59. Hartwell G, Bellizzi R. Clinical investigation of *in vivo* endodontically treated mandibular and maxillary molars. *J Endod* 1982; **8**: 555–557.
60. Wong M. Maxillary first molar with three palatal canals. *J Endod* 1991; **17**: 298–299.
61. Maggiore F, Jou YT, Kim S. A six-canal maxillary first molar: case report. *Int Endod J* 2002; **35**: 486–491.
62. Martinez-Berna A, Ruiz-Badanelli P. Maxillary first molars with six canals. *J Endod* 1983; **9**: 75–78.
63. Beatty RG. A five-canal maxillary first molar. *J Endod* 1984; **10**: 156–157.
64. Bond JL, Hartwell G, Portell FR. Maxillary first molar with six canals. *J Endod* 1988; **14**: 258–260.
65. Alani AH. Endodontic treatment of bilaterally occurring four-rooted maxillary second molars: case report. *J Can Dent Assoc* 2003; **69**: 733–735.
66. Libfeld H, Rotstein I. Incidence of four-rooted maxillary second molars: literature review and radiographic survey of 1200 teeth. *J Endod* 1989; **15**: 129–131.
67. Zmener O, Peirano A. Endodontic therapy in a maxillary second molar with three buccal roots. *J Endod* 1998; **24**: 376–377.
68. Fahid A, Taintor JF. Maxillary second molar with three buccal roots. *J Endod* 1988; **14**: 181–183.
69. Jafarzadeh H, Javidi M, Zarei M. Endodontic retreatment of a maxillary second molar with three separate buccal roots. *Aust Endod J* 2006; **32**: 129–132.
70. Pomeranz H, Fishelberg G. The secondary mesiobuccal canal of maxillary molars. *J Am Dent Assoc* 1974; **88**: 119–124.
71. Miyashita M, Kasahara E, Yasuda E, Yamamoto A. Root canal system of the mandibular incisor. *J Endod* 1997; **23**: 479–484.
72. Kartal N, Yanikoglu FC. Root canal morphology of mandibular incisors. *J Endod* 1992; **18**: 562–564.
73. Slowey RR. Root canal anatomy. Road map to successful endodontics. *Dent Clin North Am* 1979; **23**: 555–573.
74. Pecora JD, Sousa Neto MD, Saquy PC. Internal anatomy, direction and number of roots and size of human mandibular canines. *Braz Dent J* 1993; **4**: 53–57.
75. Heling I, Gottlieb-Dadon I, Chandler NP. Mandibular canine with two roots and three root canals. *Endod Dent Traumatol* 1995; **11**: 301–302.
76. Cleghorn BM, Christie WH, Dong CC. The root and root canal morphology of the human mandibular first premolar: a literature review. *J Endod* 2007; **33**: 509–516.

77. Lu TY, Yang SF, Pai SF. Complicated root canal morphology of mandibular first premolar in a Chinese population using the cross section method. *J Endod* 2006; **32**: 932–935.
78. Milano M, Chavarria C, Hoppe J. Multi-rooted mandibular premolars: report of case. *ASDC J Dent Child* 2002; **69**: 63–65.
79. Chan K, Yew SC, Chao SY. Mandibular premolar with three root canals—two case reports. *Int Endod J* 1992; **25**: 261–264.
80. Fischer GM, Evans CE. A three-rooted mandibular second premolar. *Gen Dent* 1992; **40**: 139–140.
81. Yang ZP. Multiple canals in a mandibular first premolar. Case report. *Aust Dent J* 1994; **39**: 18–19.
82. England MC Jr, Hartwell GR, Lance JR. Detection and treatment of multiple canals in mandibular premolars. *J Endod* 1991; **17**: 174–178.
83. Nallapati S. Three canal mandibular first and second premolars: a treatment approach. *J Endod* 2005; **31**: 474–476.
84. Zillich R, Dowson J. Root canal morphology of mandibular first and second premolars. *Oral Surg Oral Med Oral Pathol* 1973; **36**: 738–744.
85. El Deeb ME. Three root canals in mandibular second premolars: literature review and a case report. *J Endod* 1982; **8**: 376–377.
86. Rödig T, Hülsmann M. Diagnosis and root canal treatment of a mandibular second premolar with three root canals. *Int Endod J* 2003; **36**: 912–919.
87. De Moor RJG, Calberson FLG. Root canal treatment in a mandibular second premolar with three root canals. *J Endod* 2005; **31**: 310–313.
88. Bram SM, Fleisher R. Endodontic therapy in a mandibular second bicuspid with four canals. *J Endod* 1991; **17**: 513–515.
89. Holtzman L. Root canal treatment of mandibular second premolar with four root canals: a case report. *Int Endod J* 1998; **31**: 364–346.
90. Rhodes JS. A case of unusual anatomy: a mandibular second premolar with four canals. *Int Endod J* 2001; **34**: 645–648.
91. Macri E, Zmener O. Five canals in a mandibular second premolar. *J Endod* 2000; **26**: 304–305.
92. Pomeranz HH, Eidelman DL, Goldberg MG. Treatment considerations of the middle mesial canal of mandibular first and second molars. *J Endod* 1981; **7**: 565–568.
93. Fabra-Campos H. Three canals in the mesial root of mandibular first permanent molars: a clinical study. *Int Endod J* 1989; **22**: 39–43.
94. Wasti F, Shearer AC, Wilson NH. Root canal systems of the mandibular and maxillary first permanent molar teeth of south Asian Pakistanis. *Int Endod J* 2001; **34**: 263–266.
95. Gulabivala K, Aung TH, Alavi A, Ng YL. Root and canal morphology of Burmese mandibular molars. *Int Endod J* 2001; **34**: 359–370.
96. Baugh D, Wallace J. Middle mesial canal of the mandibular first molar: a case report and literature review. *J Endod* 2004; **30**: 185–186.
97. Ricucci D. Three independent canals in the mesial root of a mandibular first molar. *Endod Dent Traumatol* 1997; **13**: 47–49.
98. DeGrood ME, Cunningham CJ. Mandibular molar with five canals: report of a case. *J Endod* 1997; **23**: 60–62.
99. Jacobsen EL, Dick K, Bodell R. Mandibular first molars with multiple mesial canals. *J Endod* 1994; **20**: 610–613.
100. Reeh ES. Seven canals in a lower first molar. *J Endod* 1998; **24**: 497–499.
101. Kontakiotis EG, Tzanetakis GN. Four canals in the mesial root of a mandibular first molar. A case report under the operating microscope. *Aust Endod J* 2007; **33**: 84–88.
102. Beatty RG, Interian CM. A mandibular first molar with five canals: report of case. *J Am Dent Assoc* 1985; **111**: 769–771.
103. Stroner WF, Remeikis NA, Carr GB. Mandibular first molar with three distal canals. *Oral Surg Oral Med Oral Pathol Oral Radiol Endod* 1984; **57**: 554–557.
104. Friedman S, Moshonov J, Stabholz A. Five root canals in a mandibular first molar. *Endod Dent Traumatol* 1986; **2**: 226–228.
105. Calberson FL, De Moor RJG, Deroose CA. The radix entomolaris and paramolaris: clinical approach in endodontics. *J Endod* 2007; **33**: 58–63.
106. Carlsen O, Alexandersen V. Radix paramolaris in permanent mandibular molars: identification and morphology. *Scand J Dent Res* 1991; **99**: 189–195.
107. Curzon ME. Three-rooted mandibular permanent molars in English Caucasians. *J Dent Res* 1973; **52**: 181.
108. Sperber GH, Moreau JL. Study of the number of roots and canals in Senegalese first permanent mandibular molars. *Int Endod J* 1998; **31**: 112–116.
109. Yew SC, Chan K. A retrospective study of endodontically treated mandibular first molars in a Chinese population. *J Endod* 1993; **19**: 471–473.
110. Curzon MEJ, Curzon AJ. Three-rooted mandibular molars in the Keewatin Eskimo. *J Can Dent Assoc* 1971; **37**: 71–72.
111. Ribeiro FC, Consolaro A. Importancia clinica y antropologica de la raiz distolingual en los molares inferiores permanentes. *Endodoncia* 1997; **15**: 72–78.
112. De Moor RJG, Deroose CAJG, Calberson FLG. The radix entomolaris in mandibular first molars: an endodontic challenge. *Int Endod J* 2004; **37**: 789–799.
113. Manning SA. Root canal anatomy of mandibular second molars. Part I. *Int Endod J* 1990; **23**: 34–39.
114. Beatty RG, Krell K. Mandibular molars with five canals: report of two cases. *J Am Dent Assoc* 1987; **114**: 802–804.
115. Weine FS. The C-shaped mandibular second molar: incidence and other considerations. *J Endod* 1998; **24**: 372–375.
116. Cooke HG, Cox FL. C-shaped canal configurations in mandibular molars. *J Am Dent Assoc* 1979; **99**: 836–839.

117. Yang ZP, Yang SF, Lin YC, Shay JC, Chi CY. C-shaped root canals in mandibular second molars in a Chinese population. *Endod Dent Traumatol* 1988; **4**: 160–163.
118. Fan B, Cheung GSP, Fan M, Gutmann JL, Bian Z. C-shaped canal system in mandibular second molars: part I—anatomical features. *J Endod* 2004; **30**: 899–903.
119. Carver K, Nusstein J, Reader A, Beck M. *In vivo* antibacterial efficacy of ultrasound after hand and rotary instrumentation in human mandibular molars. *J Endod* 2007; **33**: 1038–1043.
120. Burleson A, Nusstein J, Reader A, Beck M. The *in vivo* evaluation of hand/rotary/ultrasound instrumentation in necrotic, human mandibular molars. *J Endod* 2007; **33**: 782–787.
121. Blum JY, Machtou P, Micallef JP. Analysis of forces developed during obturations. Wedging effect: part II. *J Endod* 1998; **24**: 223–228.
122. De Deus QD. Frequency, location, and direction of the lateral, secondary, and accessory canals. *J Endod* 1975; **1**: 361–366.
123. Rubach WC, Mitchell DF. Periodontal disease, accessory canals and pulp pathosis. *J Periodontol* 1965; **36**: 34–38.
124. Martić D, Prpic-Mehićić G, Simeon P, Pevalek J. Morphometrical analysis of main and accessory canals in apical root portion of frontal teeth. *Coll Antropol* 1998; **22**: 153–159.
125. Karagoz-Kucukay I. Root canal ramifications in mandibular incisors and efficacy of low-temperature injection thermoplasticized gutta-percha filling. *J Endod* 1994; **20**: 236–240.
126. Venturi M, Prati C, Capelli G, Falconi M, Breschi L. A preliminary analysis of the morphology of lateral canals after root canal filling using a tooth-clearing technique. *Int Endod J* 2003; **36**: 54–63.
127. Cantatore G, Varela Patiño P, Biedma BM, Ruiz Piñón M. Frecuencia e localizzazione dei canali laterali dopo otturazione canalare con GT Obturators: uno studio radiografico *in vitro*. *G It Endo* 2004; **18**: 185–191.
128. Nicholls E. Lateral radicular disease due to lateral branching of the root canal. *Oral Surg Oral Med Oral Pathol* 1963; **16**: 839–845.
129. Gen Yuan X, Zhongni Z. Filling of the lateral canal. *Oral Surg Oral Med Oral Pathol* 1984; **58**: 221–224.
130. Barkhordar RA, Stewart GG. The potential of periodontal pocket formation associated with untreated accessory root canals. *Oral Surg Oral Med Oral Pathol* 1990; **70**: 769–772.
131. Turkun M, Cengiz T. The effects of sodium hypochlorite and calcium hydroxide on tissue dissolution and root canal cleanliness. *Int Endod J* 1997; **30**: 335–342.
132. Weine FS. The enigma of the lateral canal. *Dent Clin North Am* 1984; **28**: 833–852.
133. Slowey RR. Root canal anatomy. Road map to successful endodontics. *Dent Clin North Am* 1979; **23**: 555–573.
134. Castellucci A. Endodontic radiography. In: Castellucci A, ed. *Endodontics*, Vol. 1, 2nd Edn. Florence: Tridente, 2006: 66–119.
135. Martinez-Lozano MA, Forner-Navarro L, Sanchez-Cortes JL. Analysis of radiologic factors in determining premolar root canal systems. *Oral Surg Oral Med Oral Pathol Oral Radiol Endod* 1999; **88**: 719–722.
136. Hoen MM, Hoen MM, Pink FE. Contemporary endodontic retreatments: an analysis based on clinical treatment findings. *J Endod* 2002; **28**: 834–836.
137. Nattress BR, Martin DM. Predictability of radiographic diagnosis of variations in root canal anatomy in mandibular incisor and premolar teeth. *Int Endod J* 1991; **24**: 58–62.
138. Omer OE, Al Shalabi RM, Jennings M, Glennon J, Claffey NM. A comparison between clearing and radiographic techniques in the study of the root-canal anatomy of maxillary first and second molars. *Int Endod J* 2004; **37**: 291–296.
139. Bedford JM, Martin DM, Youngson CC. Assessment of a contrast medium as an adjunct to endodontic radiography. *Int Endod J* 2004; **37**: 806–813.
140. Castellucci A. Access cavity and endodontic anatomy. In: Castellucci A, ed. *Endodontics*, Vol. 1, 2nd Edn. Florence: Tridente, 2006: 245–329.
141. Burns RC. Access openings and tooth morphology. In: Cohen S, Burns RC, eds. *Pathways of the Pulp*, 4th Edn. St. Louis: The CV Mosby Company, 1987.
142. Kulild JC, Peters DD. Incidence and configuration of canal systems in the mesiobuccal root of maxillary first and second molars. *J Endod* 1990; **16**: 311–317.
143. Baldassari-Cruz LA, Lilly JP, Rivera EM. The influence of dental operating microscopes in locating the mesiolingual canal orifices. *Oral Surg Oral Med Oral Pathol Oral Radiol Endod* 2002; **93**: 190–194.
144. Schwarze T, Baethge C, Stecher T, Geurtsen W. Identification of second canals in the mesiobuccal root of maxillary first and second molars using magnifying loupes or an operating microscope. *Aust Endod J* 2002; **28**: 57–60.
145. Buhrlay LJ, Barrows MJ, BeGole EA, Wenckus CS. Effect of magnification on locating the MB2 canal in maxillary molars. *J Endod* 2002; **28**: 324–327.
146. Yoshioka T, Kikuchi I, Fukumoto Y, Kobayashi C, Suda H. Detection of the second mesiobuccal canal in mesiobuccal roots of maxillary molar teeth *ex vivo*. *Int Endod J* 2005; **38**: 124–128.
147. Liang RZ, Wu YN, Liang RZ, Hu M. Diagnostic test study of dental operating microscope used for locating the second mesiobuccal canal orifice in maxillary first molars. *Oral Surg Oral Med Oral Pathol Oral Radiol Endod* 2007; **103**: 77–81.
148. Coehlo de Carvalho MC, Zuolo ML. Orifice locating with a microscope. *J Endod* 2000; **26**: 532–534.
149. Plotino GL, Pameijer CH, Grande NM, Somma F. Ultrasonics in endodontics: a review of the literature. *J Endod* 2007; **33**: 81–95.

150. Lea SC, Walmsley AD, Lumley PJ, Landini G. A new insight into the oscillation characteristics of endosonic files used in dentistry. *Phys Med Biol* 2004; **49**: 2095–2102.
151. Ruddle CJ. Nonsurgical endodontic retreatment. *J Endod* 2004; **30**: 827–845.
152. Clark D. The operating microscope and ultrasonics: a perfect marriage. *Dent Today* 2004; **23**: 74–81.
153. Buchanan LS. Innovations in endodontics instruments and techniques: how they simplify treatment. *Dent Today* 2002; **21**: 52–61.
154. Budd JC, Gekelman D, White GM. Temperature rise of the post on the root surface during ultrasonic post removal. *Int Endod J* 2005; **38**: 705–711.
155. Eriksson AR, Albrektsson T. Temperature threshold levels for heat-induced bone tissue injury: a vital microscopic study in the rabbit. *J Prosth Dent* 1983; **50**: 101–107.
156. Paz E, Satovsky J, Moldauer I. Comparison of the cutting efficiency of two ultrasonic units utilizing two different tips at two different power settings. *J Endod* 2005; **31**: 824–826.
157. Lin YH, Mickel AK, Jones JJ, Montagnese TA, Gonzalez AF. Evaluation of cutting efficiency of ultrasonic tips used in orthograde endodontic treatment. *J Endod* 2006; **32**: 359–361.
158. Allen RK, Newton CW, Brown CE. A statistical analysis of surgical and nonsurgical endodontic retreatment cases. *J Endod* 1989; **15**: 261–266.
159. De Moor RJG, Hommez GMG, De Boever JG, Delmé KIM, Martens GEI. Periapical health related to the quality of root canal treatment in a Belgian population. *Int Endod J* 2000; **33**: 113–120.
160. Lupi-Pegurier L, Bertrand MF, Muller-Bolla M, Rocca JP, Bolla M. Periapical status, prevalence and quality of endodontic treatment in an adult French population. *Int Endod J* 2002; **35**: 690–697.
161. Loftus JJ, Keating AP, McCartan BE. Periapical status and quality of endodontic treatment in an adult Irish population. *Int Endod J* 2005; **38**: 81–96.
162. Kabak Y, Abbott PV. Prevalence of apical periodontitis and the quality of endodontic treatment in an adult Belarusian population. *Int Endod J* 2005; **38**: 238–245.

# Biography



ELIO BERUTTI, MD, DDS

Professor and Chair of Endodontics  
School of Dentistry  
University of Turin  
Turin  
Italy

Dr. Elio Berutti received his Degree in Medicine in 1980 and his Post-Graduate Diploma in Dentistry in 1985. He has worked as an Endodontist since 1985. Professor Berutti holds the Chair of Endodontics in the School of Dentistry at the University of Turin. He is Past President of the Italian Society of Endodontics,

an Active Member of the European Society of Endodontics, and a Member of the American Association of Endodontics. Dr. Berutti is the author of many articles about Endodontics in the main journals of the field and has been a speaker at many international congresses.

---

# Biography



GIUSEPPE CANTATORE, MD, DDS

Associate Professor of Endodontics  
University of Verona  
Rome  
Italy

Professor Giuseppe Cantatore graduated with a degree in Medicine in 1980 from the University of Rome “La Sapienza”. In 1983 he specialized in General Dentistry at the same University. Dr. Cantatore taught Endodontics at the University of L’Aquila from 1987 to 1991 and at Rome “La Sapienza” from 1992 to 1998. Since 2000 he has been an Associate Professor of Endodontics at the University of Verona, Italy. Dr. Cantatore is the author of more than 90 articles, mostly related to Endodontics, published in national and international dental journals and of a book on Endodontic Intermediate Medication.

Professor Cantatore is an active member of the Italian Association of Endodontists, the Italian Association of Restorative Dentistry, and the Italian Association of

Dental Microscopy. He is an honorary member of the Libanese Society of Endodontics and an associate member of the European Association of Endodontists and the American Association of Endodontists. As an international speaker, Dr. Cantatore has given pre-congress courses, workshops, and presentations during many international meetings, among them the American Association of Endodontists, the International Federation of Endodontic Associations (IFEA), and the European Association of Endodontists (ESE). He is currently President of the European Society of Dental Microscopy, President of the Italian Society of Endodontists, and Italian Country Representative for ESE and IFEA. Dr. Cantatore has a clinical practice limited to Endodontics in Rome.

---

# Biography



ARNALDO CASTELLUCCI, MD, DDS

Visiting Professor of Endodontics  
University of Florence Dental School  
Florence  
Italy

Dr. Arnaldo Castellucci graduated with a degree in Medicine from the University of Florence in 1973 and specialized in Dentistry at the same university in 1977. From 1978 to 1980 he took continuing education courses in Endodontics at the Boston University School of Graduate Dentistry with Prof. Herbert Schilder. As well as running a practice limited to Endodontics in Florence, Dr. Castellucci is Past President of the Italian Endodontic Society, Past President of the International Federation of Endodontic Associations, an Active Member of the

European Society of Endodontology, an Active Member of the American Association of Endodontists, and a Visiting Professor of Endodontics at the University of Florence Dental School. He is the Editor of *The Italian Journal of Endodontics* and *The Endodontic Informer*, Founder and President of The Warm Gutta Percha Study Club and The Micro-Endodontic Training Center, and Editor-in-Chief of the *Endo Tribune*. An international lecturer, Dr. Castellucci is the author of the textbook *Endodontics*, which is now available in English.